



# Epithelial Membrane Antigen in Papillary Thyroid Carcinoma and Multinodular Goiter; a Marker of Discrimination

Seyed Amir Miratashi Yazdi<sup>1,2</sup>, Marjan Heshmati<sup>3</sup> and Mohammadreza Jalali Nadoushan<sup>4,\*</sup>

<sup>1</sup>School of Medicine, Shahed University, Tehran, Iran

<sup>2</sup>Sina Trauma and Surgery Research Center, Sina Hospital, Tehran University of Medical Sciences, Tehran, Iran

<sup>3</sup>Anatomy Department, Faculty of Medicine, Shahed University, Tehran, Iran

<sup>4</sup>Pathology Department, Faculty of Medicine, Shahed University, Tehran, Iran

\*Corresponding author: Pathology Department, Faculty of Medicine, Shahed University, Tehran, Iran. Email: jalalinadooshan@yahoo.com

Received 2019 July 30; Revised 2020 June 29; Accepted 2020 July 22.

## Abstract

**Background:** Papillary thyroid cancer is the most common type of thyroid malignancies. For a more accurate diagnosis, immunohistochemistry has been used widely in recent years. Epithelial membrane antigen has been detected in several benign and malignant lesions, and its use as a marker of malignancy has been sought in some studies.

**Objectives:** The current study aimed to determine the presence and level of expression of epithelial membrane antigen in papillary thyroid carcinoma and multinodular goiter.

**Methods:** Eighty-five samples of papillary thyroid carcinoma and 40 cases of multinodular goiter were stained histochemically for epithelial membrane antigen. The intensity of staining was classified in a semi-quantitative manner (1+ to 4+). Demographic data of the index cases, history of metastasis, and lymph node involvement, if any, were collected as well.

**Results:** All PTCs and 87.5% of MNGs were positive for EMA. EMA was expressed more strongly in PTCs than in MNGs ( $P < 0.00$ ). EMA reactivity was directly associated with lymph node involvement, capsular invasion, and size of the tumor ( $P = 0.008$ ,  $P < 0.001$ , and  $P < 0.001$ , respectively). The intensity level of 2 or higher had high specificity for differentiating PTC from MNG.

**Conclusions:** Strong expression of EMA may be a good marker of malignancy in differentiating PTC from MNG. This marker may also be regarded as an index of invasive behavior of PTC.

**Keywords:** Epithelial Membrane Antigen, Papillary Thyroid Carcinoma, Multinodular Goiter, Immunohistochemistry, Lymph Node Involvement, Capsular Invasion

## 1. Background

Thyroid cancer is the most common malignancy of the endocrine system (1), and its incidence has significantly increased during the last years. Among all thyroid cancers, papillary thyroid is the most frequent one and encompasses more than 80% of all index cases (2). The incidence of papillary thyroid cancer has increased 3.7 times from 1975 to 2009 (3).

Developing a prompt therapeutic strategy depends largely on the precise diagnosis of the underlying thyroid lesion and the differentiation between a benign condition and a malignancy. Traditionally, high cellularity/proliferation marked nuclear atypia, and high mitotic rate are cytomorphological features that are applied to distinguish between reactive and neoplastic pathologies (4-6). However, several studies have demonstrated that these indices could be of very limited use in certain settings, such as small biopsy specimens (7).

Immunohistochemistry is a fairly new instrument in the hand of scientists to provide them with more objective and useful information to have a more precise diagnosis. Researchers have applied immunohistochemical analyses to determine embryonic tissue origin and evaluate the state of differentiation.

Human milk fat globules that were isolated from defatted human milk are heterogeneous high weight molecules that are mostly expressed on the luminal surface membranes and represent high immunogenicity. These molecules were further called Epithelial Membrane Antigen (EMA).

Anti sera against these EMAs, that were postulated to react solely with breast tissues were further found to react with other epithelial-derived tissues as well (8) and EMA antibodies have been used afterward as markers of epithelial differentiation in malignant as well as benign pathologies (9).

Studies that were focused on the expression of EMA in different thyroid lesions have reported different expression rates and dissimilar patterns of distribution; findings that were, in some instances, discrepant (10-13). Hence, further studies seem to be necessary to investigate the independent role of this marker in histopathologic analyses of thyroid benign and malignant lesions.

## 2. Objectives

The current study aimed to establish the profile of reactivity of papillary thyroid carcinoma (PTC) and multinodular goiter (MNG) to EMA and to compare the findings in these two groups.

## 3. Methods

Specimens of patients who underwent total or partial thyroidectomy in Mostafa Khomeini Hospital between January 2011 and December 2013 were investigated. Eighty-five specimens from defined PTC and 40 samples from MNG were collected. As routine, tissues get fixed in the department of pathology using paraformaldehyde and before sectioning, got embedded in Glycerine.

Demographic data (i.e., age and gender of patients harboring the thyroid lesion along with the presence and site of distant metastasis and lymph node involvement, if any) were also retrieved from the clinical charts.

Slides with 4  $\mu$ m thickness were cut, deparaffinized, and incubated in methanol containing hydrogen peroxidase for 30 minutes to block the endogenous peroxidase activity. Then were further washed with phosphate-buffered saline and placed in Tris-buffered saline with 2 percent horse serum. Slides were subsequently incubated with the monoclonal antibody against EMA for 18 hours (Novacastra, UK) and were further assessed under light microscopy.

Intensity of the reaction was subsequently classified based on the percentage of the total cells that had positive staining; +++++, more than 90%; +++, 50% - 90%; ++, 11% - 50%; +: 1% - 10% of the cells stained (13).

Data then were entered in the commercially available biostatistical software (SPSS V.14, IBM SPSS, N.Y., and the USA) and descriptive and analytic analyses were performed. A P-value < 0.05 was considered as statistically significant.

## 4. Results

On average, patients with PTC were older than those with MNG ( $40.34 \pm 1.69$  versus  $32.42 \pm 1.1$ ;  $P = 0.002$ ). More

than two-thirds of patients in both groups were female; 85.88 and 75% of patients with PTC and MNG, respectively. Eighty-five PTCs and forty multinodular goiters received tissue processing and further assessment. All PTCs (100%) and 87.5% of multinodular goiters were positive for EMA ( $P < 0.001$ ).

More than 90% of the cells of 5.8% of PTCs were reactive to the antisera to EMA, while the incidence in multinodular goiters was 0%; the difference was statistically significant ( $P < 0.001$ ). Overall, the intensity of staining was more in PTCs than in MNGs ( $P < 0.001$ ). The results of both categories are expressed in detail in Table 1.

**Table 1.** The Intensity of Reaction to EMA Antisera in PTC and MNG

Type of Lesion	Intensity of Reaction				
	No Reaction	+	++	+++	++++
PTC	0	24	37	19	5
MNG	5	18	17	0	0

Abbreviations: EMA, epithelial membrane antigen; MNG, multinodular goiter; PTC, papillary thyroid carcinoma.

Of all patients with PTCs, 63 (85%) had positive lymph nodes. And positive lymph node was directly associated with more intense staining for EMA ( $P = 0.008$ ) (Figure 1).

The capsular invasion was observed in 42 (49.4%) of samples and more intense staining was detected in the presence of capsular invasion ( $P < 0.001$ ).

The mean size of the tumor was also directly associated with the immune reactivity of the papillary thyroid carcinoma to Anti EMA ( $P = 0.001$ ). Even after performing the multivariate analysis (linear regression) and eliminating the effect of confounding variable (capsular invasion and lymph node involvement) this association was significant.

ROC analysis showed a good diagnostic value of EMA (area: 0.724,  $P = 0$ ), and EMA at an intensity level of 2 or higher had high specificity for EMA (Figure 2).

## 5. Discussion

Due to the overlapping morphological features between malignant and benign thyroid lesions, the application of markers of malignancy for a net diagnosis was inevitable. Researchers have shown that characterizing features of malignancy might be shared in benign lesions. Moreover, the detection of many of these criteria depends on the subjective interpretation of the pathologist.

In the study conducted by Lloyd and colleagues, optically clear nuclei of papillary carcinoma, which is a critical feature of papillary carcinoma, was reported in hyperfunctioning lesions as well (14).

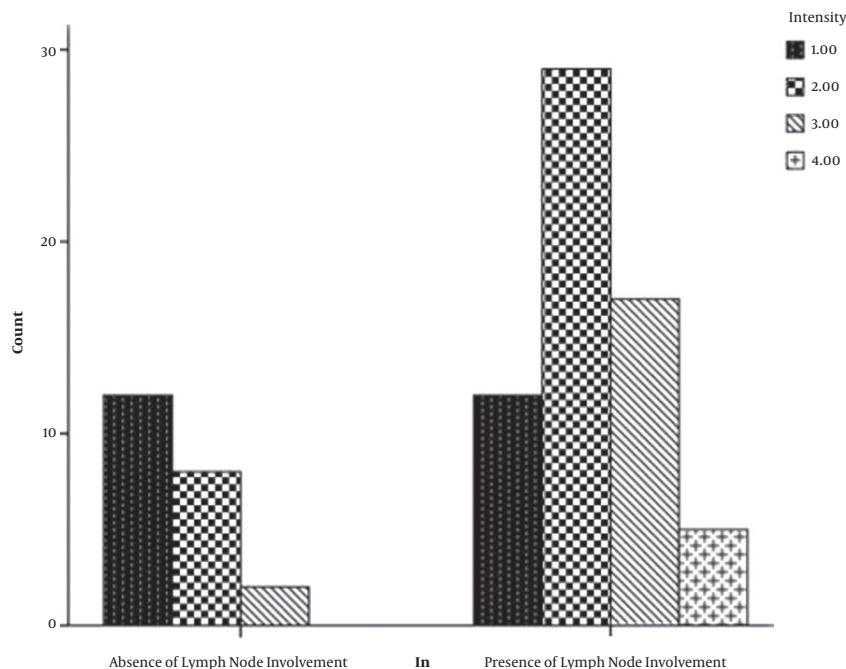


Figure 1. Distribution of the reactivity strength to EMA antisera regarding lymph node involvement.

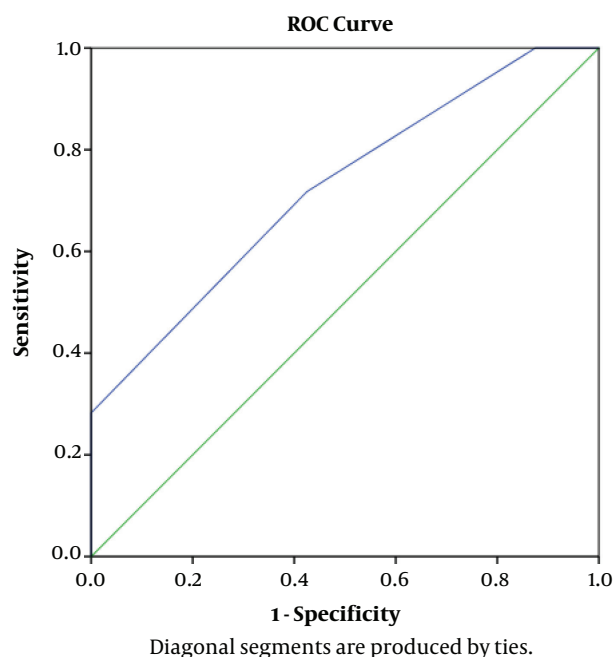


Figure 2. ROC curve comparing PTC vs. MNG

EMA that was first detected histochemically in epithelial tissues, got importance as a potential effective marker to establish the epithelial nature of neoplasms. In a study conducted by Pinkus and Kurtin, 320 specimens of a wide variety of neoplasms underwent immunoreactive assessment for EMA. Saved for malignant lymphomas (Hodgkin's and non-Hodgkin's types), endocrine neoplasms, malignant melanomas, and some soft tissue tumors, all other malignancies were positive for EMA (10).

Further studies were designed to investigate the role of EMA in differentiating malignant and benign lesions. In a study that is performed in 1999, scientists used antibodies against EMA, P53, and bcl-2 to differentiate mesothelial benign and malignant conditions. They concluded that linear staining for EMA is a good marker to discriminate epithelioid malignant mesothelioma and mesothelioma from reactive mesothelial hyperplasia. Nevertheless, weak focal staining with anti-EMA was observed in reactive conditions as well (14).

EMA has also been useful in discriminating malignant conditions. In a study performed by Dejmak and Hjerpe, the authors compared the pattern of expression of different immunohistochemical markers in malignant mesothelioma and adenocarcinoma. To do this, they utilized four histochemical markers, including EMA, which had a 79% sensitivity and 100% specificity in the diagnosis

of malignant mesothelioma (15).

Few studies also had investigated the EMA in different thyroid lesions. In a study performed by Damiani and colleagues, the researchers sought the presence and distribution of EMA and alcianophilic substances in 17 cases of papillary thyroid carcinoma and 14 cases of benign thyroid lesions and found these two markers "useful" in differentiating benign from malignant events (16). The findings of the current study also support the finding of this study.

In our study, overall positivity was significantly higher in PTCs in comparison to MNGs. Besides, the intensity of staining was significantly higher in PTCs than in MNGs.

In another study, the authors focused on the value of EMA for a concrete diagnosis between papillary neoplasia and papillary hyperplasia and found co-expression of S-100 and EMA as valuable markers to distinguish between these two situations. In this study, the strength of expression of both markers was of paramount importance in distinguishing malignant from benign lesions (17).

Not only in discriminating benign and malignant situations, but also in predicting metastasis, EMA has been found to be useful.

In a study performed by Yamamoto and colleagues on 74 patients with PTC with occult/distant metastasis and no metastasis, the researchers reported a higher rate of EMA expression in samples from patients with distant metastasis and concluded that EMA might be a useful marker in anticipating the presence of distant metastasis (13).

In the current study, lymph node involvement, capsular invasion, and tumor size were all positively associated with higher EMA reactivity.

These findings indicate that the expression of EMA, besides the strength of this expression, might be a useful index of invasive behavior in PTCs.

### 5.1. Conclusion

In conclusion, the results of the current study support the findings of previous studies that a strong expression of EMA may be a good marker of malignancy in thyroid lesions, particularly in PTC. The intensity of staining was also associated with invasive behavior of the tumor-like lymph node involvement and capsular invasion.

### Footnotes

**Authors' Contribution:** All authors contributed to all aspects of the article.

**Conflict of Interests:** The authors declare no conflict of interest.

**Ethical Approval:** In this study, all procedures involving human participants were conducted in accordance with

the ethical standards of Shahed University's Ethics Committee and National Ethics Committee as well as the 1964 Helsinki declaration and its later amendments or comparable ethical standards.

**Funding/Support:** This research received no funding support.

### References

- Nikiforov YE. Thyroid carcinoma: molecular pathways and therapeutic targets. *Mod Pathol*. 2008;**21 Suppl 2**:S37-43. doi: [10.1038/modpathol.2008.10](https://doi.org/10.1038/modpathol.2008.10). [PubMed: [18437172](https://pubmed.ncbi.nlm.nih.gov/18437172/)]. [PubMed Central: [PMC2673022](https://pubmed.ncbi.nlm.nih.gov/PMC2673022/)].
- Memon A, Darif M, Al-Saleh K, Suresh A. Epidemiology of reproductive and hormonal factors in thyroid cancer: evidence from a case-control study in the Middle East. *Int J Cancer*. 2002;**97**(1):82-9. doi: [10.1002/ijc.1573](https://doi.org/10.1002/ijc.1573). [PubMed: [11774247](https://pubmed.ncbi.nlm.nih.gov/11774247/)].
- Davies L, Welch HG. Current thyroid cancer trends in the United States. *JAMA Otolaryngol Head Neck Surg*. 2014;**140**(4):317-22. doi: [10.1001/jamaoto.2014.1](https://doi.org/10.1001/jamaoto.2014.1). [PubMed: [24557566](https://pubmed.ncbi.nlm.nih.gov/24557566/)].
- Enzinger FM. *Soft tissue tumors*. 5th ed. St Louis: Mosby; 1988. p. 502-8.
- Galateau-Salle F. *Pathology of malignant mesothelioma*. Springer Science & Business Media; 2010.
- McCaughey W, Al-Jabi M. Differentiation of serosal hyperplasia and neoplasia in biopsies. *Pathol Annu*. 1986;**21**:271.
- Mangano WE, Cagle PT, Churg A, Vollmer RT, Roggli VL. The diagnosis of desmoplastic malignant mesothelioma and its distinction from fibrous pleurisy: a histologic and immunohistochemical analysis of 31 cases including p53 immunostaining. *Am J Clin Pathol*. 1998;**110**(2):191-9. doi: [10.1093/ajcp/110.2.191](https://doi.org/10.1093/ajcp/110.2.191). [PubMed: [9704618](https://pubmed.ncbi.nlm.nih.gov/9704618/)].
- Ormerod MG, Steele K, Westwood JH, Mazzini MN. Epithelial membrane antigen: partial purification, assay and properties. *Br J Cancer*. 1983;**48**(4):533-41. doi: [10.1038/bjc.1983.226](https://doi.org/10.1038/bjc.1983.226). [PubMed: [6626453](https://pubmed.ncbi.nlm.nih.gov/6626453/)]. [PubMed Central: [PMC2011505](https://pubmed.ncbi.nlm.nih.gov/PMC2011505/)].
- Sloane JP, Ormerod MG. Distribution of epithelial membrane antigen in normal and neoplastic tissues and its value in diagnostic tumor pathology. *Cancer*. 1981;**47**(7):1786-95. doi: [10.1002/1097-0142\(19810401\)47:7<1786::aid-cnrcr2820470711>3.0.co;2-8](https://doi.org/10.1002/1097-0142(19810401)47:7<1786::aid-cnrcr2820470711>3.0.co;2-8).
- Pinkus GS, Kurtin PJ. Epithelial membrane antigen—A diagnostic discriminant in surgical pathology: Immunohistochemical profile in epithelial, mesenchymal, and hematopoietic neoplasms using paraffin sections and monoclonal antibodies. *Human Pathology*. 1985;**16**(9):929-40. doi: [10.1016/s0046-8177\(85\)80132-5](https://doi.org/10.1016/s0046-8177(85)80132-5).
- Sloane JP, Ormerod MG, Neville AM. Potential pathological application of immunocytochemical methods to the detection of micrometastases. *Cancer Res*. 1980;**40**(8 Pt 2):3079-82. [PubMed: [7397703](https://pubmed.ncbi.nlm.nih.gov/7397703/)].
- Wilson NW, Pambakian H, Richardson TC, Stokoe MR, Makin CA, Heyderman E. Epithelial markers in thyroid carcinoma: an immunoperoxidase study. *Histopathology*. 1986;**10**(8):815-29. doi: [10.1111/j.1365-2559.1986.tb02580.x](https://doi.org/10.1111/j.1365-2559.1986.tb02580.x). [PubMed: [2428725](https://pubmed.ncbi.nlm.nih.gov/2428725/)].
- Yamamoto Y, Izumi K, Otsuka H. An immunohistochemical study of epithelial membrane antigen, cytokeratin, and vimentin in papillary thyroid carcinoma. Recognition of lethal and favorable prognostic types. *Cancer*. 1992;**70**(9):2326-33. doi: [10.1002/1097-0142\(19921101\)70:9<2326::aid-cnrcr2820700919>3.0.co;2-d](https://doi.org/10.1002/1097-0142(19921101)70:9<2326::aid-cnrcr2820700919>3.0.co;2-d).
- Cury PM, Butcher DN, Corrin B, Nicholson AG. The use of histological and immunohistochemical markers to distinguish pleural malignant mesothelioma and in situ mesothelioma from reactive mesothelial hyperplasia and reactive pleural fibrosis. *The Journal of Pathology*. 1999;**189**(2):251-7. doi: [10.1002/\(sici\)1096-9896\(199910\)189:2<251::aid-path412>3.0.co;2-f](https://doi.org/10.1002/(sici)1096-9896(199910)189:2<251::aid-path412>3.0.co;2-f).

15. Dejmek A, Hjerpe A. The combination of CEA, EMA, and BerEp4 and hyaluronan analysis specifically identifies 79% of all histologically verified mesotheliomas causing an effusion. *Diagn Cytopathol.* 2005;**32**(3):160–6. doi: [10.1002/dc.20202](https://doi.org/10.1002/dc.20202). [PubMed: [15690331](https://pubmed.ncbi.nlm.nih.gov/15690331/)].
16. Damiani S, Fratamico F, Lapertosa G, Dina R, Eusebi V. Alcian blue and epithelial membrane antigen are useful markers in differentiating benign from malignant papillae in thyroid lesions. *Virchows Arch A Pathol Anat Histopathol.* 1991;**419**(2):131–5. doi: [10.1007/BF01600226](https://doi.org/10.1007/BF01600226). [PubMed: [1871955](https://pubmed.ncbi.nlm.nih.gov/1871955/)].
17. Mitselou A, Vougiouklakis TG, Peschos D, Dallas P, Boumba VA, Agnantis NJ. Immunohistochemical study of the expression of S-100 protein, epithelial membrane antigen, cytokeratin and carcinoembryonic antigen in thyroid lesions. *Anticancer Res.* 2002;**22**(3):1777–80. [PubMed: [12168868](https://pubmed.ncbi.nlm.nih.gov/12168868/)].