

Familial Hypophosphatemic Rickets and Hypopituitarism: A Case Report and Literature Review

Behnaz Khazai,¹ and Rahim Vakili^{1,*}

¹Department of Pediatrics, Imam Reza Hospital, Mashhad University of Medical Sciences, Mashhad, IR Iran

*Corresponding author: Rahim Vakili, Department of Pediatrics, Imam Reza Hospital, Mashhad University of Medical Sciences, P. O. Box: 91379-13316, Mashhad, IR Iran. Tel: +98-5138593045, Fax: +98-5138591057, E-mail: Vakilir@mums.ac.ir

Received 2014 March 03; Revised 2014 September 04; Accepted 2015 March 04.

Abstract

Introduction: Coincided familial hypophosphatemic rickets (FHR) and Hypopituitarism is a rare condition. Growth hormone deficiency (GHD) evaluation has been advocated for refractory FHR cases, considering the possible masking effect of FHR on the former. Moreover, there has been controversial use of growth hormone as an adjunct therapy in FHR.

Case Presentation: A 19-month-old girl was presented with severe growth failure, refractory to 6 months of vitamin D therapy for assumed nutritional rickets. Following detection of low serum phosphate, insulin-like growth factor-1 (IGF-1) and insulin-like growth factor-binding protein 3 (IGFBP3), phosphaturia and positive FHR family history, she was diagnosed with concomitant FHR and hypopituitarism.

Conclusions: This case highlights the fact that FHR and GHD may coexist, with possible masking effect of one on the other, thereby misleading the approach, posing large impacts on therapy, which has historically been a difficult challenge in FHR patients.

Keywords: Familial Hypophosphatemic Rickets, Growth Hormone, Hypopituitarism, Vitamin D

1. Introduction

Familial hypophosphatemic rickets (FHR), originally called vitamin D resistant rickets, is the most common heritable form of rickets, with an incidence of 1 in 20000 births (1). It is a heterogeneously inherited disorder, with the X-linked form being the most common. Genetic abnormalities underlying X-linked, autosomal recessive (types 1 and 2) and autosomal dominant forms, seem to share a common pathway, involving high fibroblast growth factor 23 (FGF23) serum levels. The FGF23 is a phosphatonin, the over activity of which has been shown to be associated with reduced renal and intestinal phosphate absorption and decreased synthesis, and increased degradation of 1,25 dihydroxy vitamin D (2-4), for which FGF23 plays role as a counter regulator (5-8). The FHR most commonly presents in childhood, with characteristic clinical and radiologic features of osteomalacia.

Hypopituitarism, with an incidence and prevalence of four and 46 per 100000 per year (9), is the partial or complete deficiency of single or multiple hormones of the posterior or anterior pituitary gland. The etiology may be classified as pituitary diseases, hypothalamic diseases, traumatic brain injury or stroke. The vast number of genes, whose coordinated temporal and spatial expression is essential for proper structural development and function of the hypothalamic-pituitary axis, could be subject to a variety of mutations, with resultant hormone deficiencies, to

different extents. Among the anterior pituitary hormones, Growth Hormone Deficiency (GHD) is the most common affliction, usually undiagnosed before 2 years of age, when it manifests as short stature and decreased growth velocity. Idiopathic GHD is divided into 3 types, based on clinical presentation and inheritance pattern.

2. Case Presentation

A 19-month-old girl was presented to the Imam Reza hospital, Mashhad, Iran, in June 2013, with severe growth failure, refractory to 6 months of vitamin D therapy for assumed nutritional rickets. She was born through normal vaginal delivery, without history of any problems during pregnancy and labor. She had received phototherapy for a total bilirubin of 13 on the second day of life and was discharged with a total bilirubin of 9. Her birth weight, height and head circumference were 2100 g, 48 cm and 33 cm, respectively, which were in the 0.2, 5.2, 1.5 percentiles with Z scores of -2.9, -1.6, -2.2 (Table 1), [measured by Seca infantometer, (Seca, Hamburg, Germany)], respectively (Table 1). Her vaccination was complete, according to the national protocol. She belonged to a family tree with ubiquitous consanguineous marriages and her parents were cousins (Figure 1). She was the second child of the family, the first being 8 years old with developmental delay manifested as inability to catch on school and speech problems (inability to make full sentences), without a specific diagnosis.

Table 1. Z Score and Percentile for Weight, Height and Head Circumference at Birth and 18 Months

	At Birth	Z Score at Birth	Percentile at Birth	18 Months	Z Score at 18 Months	Percentile at 18 Months
Weight, g	2100	-2.9	0.2	6700	-5.7	0.1
Height, cm	48	-1.6	5.2	66	-4.7	0.1
Head circumference, cm	33	-2.2	1.5	46	-0.6	27.8

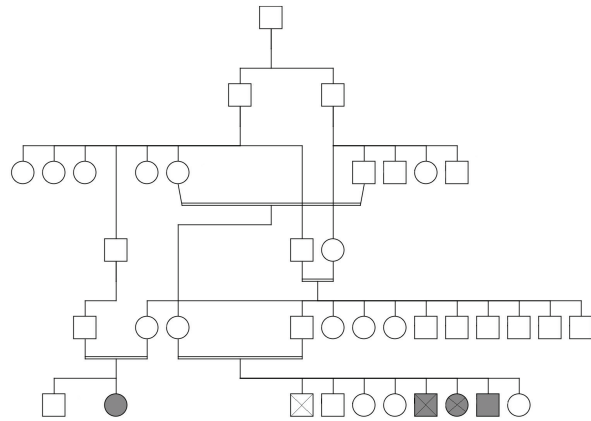


Figure 1. Family Tree

Our patient did not have any problems until 6 months of age, when gradually she was noticed to have growth delay, on regular monthly neonatal checkups. She was referred to a secondary center when she was 1 year old. She was diagnosed with nutritional rickets and vitamin D therapy, with a dose of 300000 units, was instituted for her, which did not turn out to be effective. Finally, she was referred to our clinic, when she was 18 months old. From a neurodevelopmental viewpoint, she was still unable to walk. According to the parents, she had no head lag at 4 months, was able to sit without support at 6 months, and able to stand at 18 months. Although she could pronounce DaDa, she was still unable to say any word. She had no history of vomiting and diarrhea. Her weight, height and head circumference were 6700 g, 66 cm and 46 cm, respectively, which were in the 0.1, 0.1, 27.8 percentiles with Z scores of -5.7, -4.7, -0.6 (Seca, Hamburg, Germany), respectively (Table 1). On physical examination, she had an apparent short stature for her age, which, together with her facial features, including prominent forehead, depressed midface and relatively small ratios, raised the suspicion of growth hormone deficiency (GHD) (Figures 2 and 3). Her tibia and fibula regions seemed a bit bowed and subtle rosaries were apparent on her costochondral junctions, she had normal genitalia.

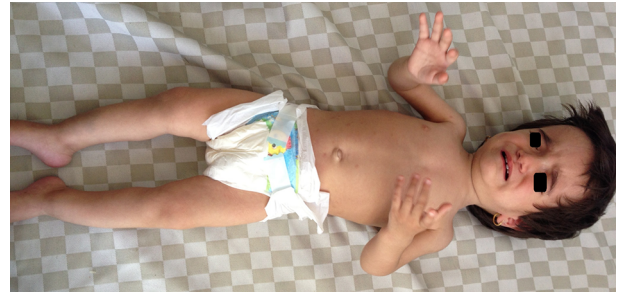

Figure 2. A 19-Month-Old Girl Patient

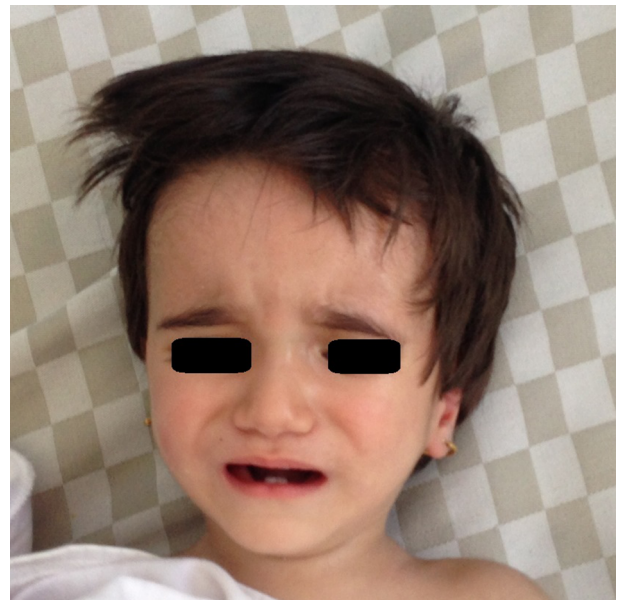

Figure 3. Depressed Midface

Two X-rays of the wrist region, when she was 12 months old, reported severe and significant fraying of radial and ulnar metaphyses, compatible with advanced rickets and a bone age of 9 months (Figures 4 and 5). On laboratory results, she was found to be hypophosphatemic and phosphaturic. Her cousin turned out to be under treatment in our center for FHR (Figure 1), which raised the possibil-

ity that this heritable disease could explain her refractoriness toward vitamin D therapy. Her other laboratory results showed normal blood gases, BUN and Creatinine, while her pituitary function results were compatible with isolated GHD, with the other hypophyseal hormones being within the normal ranges (Table 2).

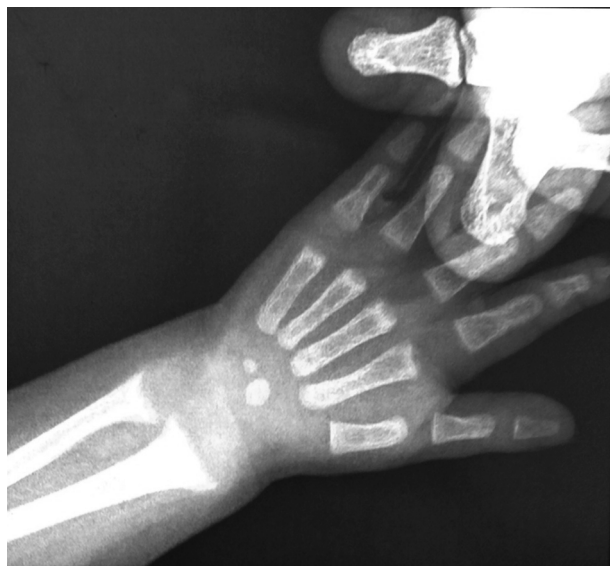

Figure 4. X-ray of the wrist region

A brain magnetic resonance imaging (MRI) was requested to rule out anatomical lesions and tumors. The sella turcica region was normal and symmetric, with midline infundibulum position. Hypophyseal parenchyma had normal signal, with evidence of neither micro- nor macroadenoma. No midline anomaly was noticed.

Finally, with a diagnosis of both FHR and GHD, she was put on a regimen constituted of 0.9 mg/day growth hormone (GH), 0.5 mg/day calcitriol and 500 mg/day phosphate. She was put on a regular follow-up schedule for therapeutic adjustment, according to her response to therapy.

3. Discussion

Familial Hypophosphatemic Rickets (FHR), classically called vitamin D resistant rickets, due to its refractoriness to vitamin D therapy while clinically mimicking nutritional rickets, is the most common heritable rickets. It is often misdiagnosed as nutritional rickets, metaphyseal dysplasia and physiologic bowing (2). Although the most apparent abnormality is renal phosphate wasting, due to reduced expression of sodium-phosphate cotransporters

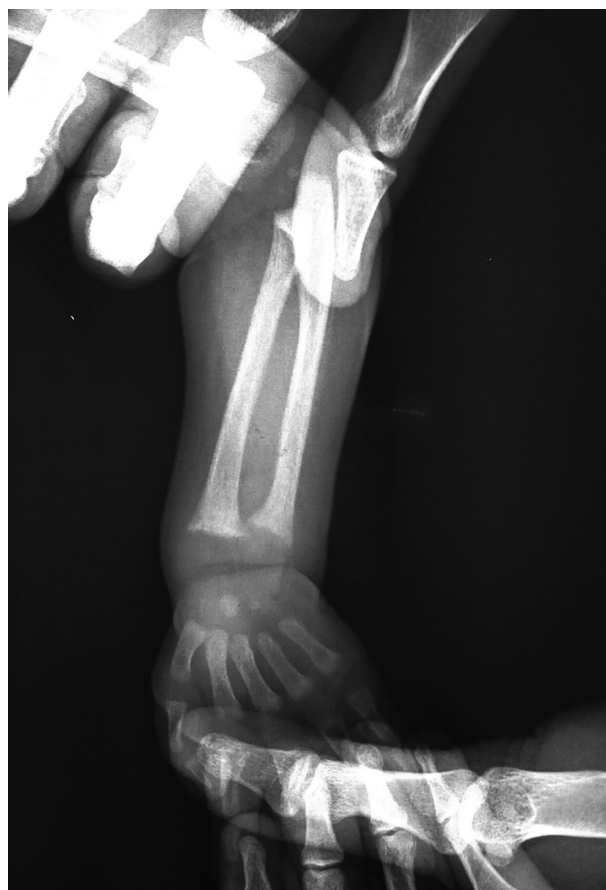

Figure 5. X-ray of the wrist region

(NaPi-IIa and NaPi-IIc, members of the type II sodium-phosphate symporter family) on the apical surface of proximal renal tubule cells (10, 11), phosphate transport may also be impaired in other cells, particularly osteoblasts (12).

The most common form is X-linked, with an incidence of 1 in 20000 births (1). Inactivating mutations of PHEX, DMP1, ENPPI and activating mutations of FGF23 gene are associated with X-linked, autosomal recessive type 1, autosomal recessive type 2 and autosomal dominant hypophosphatemic rickets, respectively (13). The PHEX mutations have been found in 87% of familial and 72% of sporadic cases (14, 15). Over activity of FGF23 may be the primary cause of FHR, as suggested by its increased level in XL-FHR, through yet unknown mechanisms, although an increase in its uncleaved full-length form, with PHEX mutation and a common pathway through FGF receptor for PHEX and DMP1 has been proposed (16-18). The FGF23 produced by osteocytes and osteoblasts is one of the so-called phosphatonins including FGF7, DMP1, MEPE, sFRP-4 and Klotho (19),

Table 2. Laboratory Results

	Patients Value	Reference Range (Corrected for Age)
pH	7.38	
PCO ₂	29.8	
HCO ₃	18	
T4 (total), micg/dL	6	5.9 - 17.2
TSH, micIU/mL	1.7	0.4 - 3.6
Cortisol, microg/dL	7.3	Mornings: 9.4 - 26; Evenings: 1.8 - 12.6
ACTH, pg/mL	18	7.2 - 63.3
IGF-1, ng/mL	< 5	49 - 171
GH, mIU/L	6.9	Up to 20
IGFBP-3, ng/mL	552	1481 - 4481
BUN, mg/dL	9.46	5 - 18
Creatinine, mg/dL	0.83	0.5 - 1.2
Ca, mg/dl	8.4	8.4 - 10.4
Phosphorus, mg/dL	2.6	3.5 - 7
ALP, U/L	1715	180 - 1200
Urinary phosphate, mg/24 h	1530	400 - 1300

Abbreviations: ACTH, adrenocorticotrophic hormone; ALP, alkaline phosphatase; BUN, blood urea nitrogen; Ca, calcium; GH, growth hormone; HCO₃, bicarbonate; IGF-1, insulin-like growth factor 1; IGFBP-3, insulin-like growth factor-binding protein 3; PCO₂, carbon dioxide arterial pressure; TSH, thyroid-stimulating hormone; T4, thyroxin.

of which the evolutionary relevance with PHEX, DMP1, MEPE and ASARM peptides has been a subject of study (20). It reduces renal and intestinal phosphate absorption, decreases synthesis and increases catabolism of 1, 25 dihydroxy vitamin D (2-4), acting as a counter regulator of the latter (5-8). In accordance with the role of FGF23, tumor-induced Osteomalacia, a paraneoplastic syndrome with similar hypophosphatemic features, is caused by its ectopic production (2) and its deficiency has been implicated in hyperphosphatemic tumoral calcinosis (4, 21).

The FHR most commonly presents in childhood, with bowing of the legs and osteomalacia, if left untreated. With progressive bowing, antero-medial rotational torsion of tibiae, short stature and rosaries may be found at costochondral junction of the ribs. Metaphyseal changes of rickets are usually evident on radiographs, including widening, cupping and fraying of metaphyses and coarsening of the trabecular pattern. Growth retardation is common, although it is not a constant finding, with variable presentations (18). Biochemical findings are hypophosphatemia, low to normal circulating 1, 25 (OH)₂ D levels, elevated

serum alkaline phosphatase activity in children (but not to the degree observed in vitamin D deficient rickets) and normal serum calcium and circulating 25-OH vitamin D. Later life findings are dental abscesses, arthritis and calcification of tendons and ligaments (enthesopathy) (2).

Treatment consists of long-term phosphate and calcitriol (2, 12, 22). Despite ameliorating, this would not completely resolve the condition. The GH has been used as an adjunct therapy, even though its efficacy and possible side effects are controversial (2, 18, 23-25). It has also been proposed that GH production should be evaluated in poorly growing FHR patients, due to possible masking effect of the latter on GH deficiency (26). Use of anti-FGF23 neutralizing antibodies has also been under consideration, as future treatment potential (2, 13, 27).

Hypopituitarism refers to partial or complete deficiency of single or multiple hormones of either posterior or anterior hypophysis. The etiology may be classified as pituitary disorders [mass lesions, radiation, surgery, infiltrative lesions, infarction (Sheehan's syndrome), apoplexy, abscess, and genetic], hypothalamic disorders (mass lesions, infiltrative lesions, radiation, and infections), traumatic brain injury and stroke. The only population based study to date reports an incidence and prevalence of 4 and 46 per 100000 per year, respectively (9). The coordinated expression of a series of genes, in a specific temporal and spatial pattern is essential for proper structural development and function of the anterior pituitary gland. Mutations here would affect one or several cell types, leading to hormone deficiencies. Pituitary developmental factors genes causing combined pituitary hormone deficiencies include: *Hesx1*, *Lhx3*, *Lhx4*, *Otx2*, *Pitx2*, *POU1F1*, *Prop-1*, and *Six6* (28). An example of single cell type gene is *GH1*, leading to isolated GH deficiency (IGHD) type 2, the common autosomal dominant form (29). Based on clinical presentation and inheritance patterns, IGHD is divided into three types.

Among anterior pituitary hormones, GHD is the most common which usually does not manifest until after 2 years of age, with short stature and decreased growth velocity. Newborns with hypopituitarism may present in first days of life with hypoglycemia, hypothermia, conjugated hyperbilirubinemia, electrolyte abnormalities, and boys with GHD or gonadotropin deficiency may present with micropenis. Midline defects should raise the suspicion for hypopituitarism, including holoprosencephaly, cleft lip/palate or radiologic evidence of absent corpus callosum or septum pellucidum (29). Older children present with either short stature or decreased growth velocity. Severe GHD may cause characteristic facial features, including prominent forehead, depressed midface and delayed dentition (28-30). In one study, GHD patients showed sig-

nificantly smaller linear values for all facial structures, while dental maturity and eruption were delayed for 1.2 and 1.3 y, respectively (31). The GH therapy has been shown to improve facial growth in these patients (32, 33). In older children and adults there would be abnormalities of protein, fat and carbohydrate metabolisms, which may manifest as central obesity, decreased lean mass and low mineral density, abnormal lipid profiles, premature atherosclerosis, decreased quality of life, and increased mortality. Recently, case reports and several clinical studies suggest that GHD state in adults is associated with an increased prevalence of nonalcoholic fatty liver disease (NAFLD) and subsequently, non-alcoholic steatohepatitis (NASH) or liver cirrhosis (34).

Auxology and clinical judgment constitute the basis of diagnosis, due to the lack of a true gold standard. Provocative testing (e.g. ITT) is poorly reproducible, depending on factors such as body composition and pubertal status and is limited by significant variability among commercially available GH assays. The IGF1 and IGFBP3 levels are useful in combination with other measurements (35). Children with congenital and near complete GHD present with severe growth failure, delayed bone age, and very low serum levels of GH, IGF1 and IGFBP3 whereas milder growth failure and decrease in IGF1 and IGFBP3 could be seen in other causes of growth failure such as poor nutrition. Brain MRI is recommended for suspected GHD and when GHD diagnosis is made clinically and biochemically. It could help determining the etiology, showing possible morphological abnormalities and predicting GHD permanency (36). Regardless of the initial presentation, follow-up should be continuous considering the risk of developing additional hormone deficiencies (29). Up to 67% of children with idiopathic GHD showed normal test results following cessation of therapy as adults (12) and retesting them is advised (37, 38).

We reported on a 19 month old girl who presented to our clinic with severe growth failure refractory to 6 months of vitamin D therapy for assumed nutritional rickets. After a thorough history and laboratory evaluation, she was found to have low serum phosphate levels and a cousin with FHR who had been under treatment in our center. Considering her prominent refractory growth failure and suspicious facial features she was assessed for IGF1 and IGFBP3 levels which turned out to be significantly decreased. Finally, she was diagnosed with both FHR and GHD which is a rare coincidence. To our knowledge, there has been reported only one report of GHD and hypophosphatemic rickets, in a case with oculocerebrorenal Syndrome of Lowe, together (39). Unfortunately, we were unable to perform a genetic analysis for this patient and her family tree. Besides the controversial efficacy and safety of

GH therapy in FHR patients (2, 23-25), it has also been previously pointed out that GH production should be evaluated in poorly growing FHR patients due to FHR's masking effect on GHD (26). This highlights the fact that these two conditions may coexist in one patient, posing large impacts on the treatment approach, which has been a difficult challenge in FHR patients.

Footnote

Authors' Contribution: Study concept, design, supervision and final revision: Rahim Vakili; data acquisition, drafting of manuscript and literature review: Behnaz Khazai.

References

1. Alizadeh Naderi AS, Reilly RF. Hereditary disorders of renal phosphate wasting. *Nat Rev Nephrol.* 2010;**6**(11):657-65. doi: [10.1038/nrneph.2010.121](https://doi.org/10.1038/nrneph.2010.121). [PubMed: 20924400].
2. Carpenter TO, Imel EA, Holm IA, Jan de Beur SM, Insogna KL. A clinician's guide to X-linked hypophosphatemia. *J Bone Miner Res.* 2011;**26**(7):1381-8. doi: [10.1002/jbmr.340](https://doi.org/10.1002/jbmr.340). [PubMed: 21538511].
3. Prie D, Friedlander G. Reciprocal control of 1,25-dihydroxyvitamin D and FGF23 formation involving the FGF23/Klotho system. *Clin J Am Soc Nephrol.* 2010;**5**(9):1717-22. doi: [10.2215/CJN.02680310](https://doi.org/10.2215/CJN.02680310). [PubMed: 20798257].
4. Saito T, Fukumoto S. Fibroblast Growth Factor 23 (FGF23) and Disorders of Phosphate Metabolism. *Int J Pediatr Endocrinol.* 2009;**2009**:496514. doi: [10.1155/2009/496514](https://doi.org/10.1155/2009/496514). [PubMed: 19956747].
5. Liu S, Tang W, Zhou J, Stubbs JR, Luo Q, Pi M, et al. Fibroblast growth factor 23 is a counter-regulatory phosphaturic hormone for vitamin D. *J Am Soc Nephrol.* 2006;**17**(5):1305-15. doi: [10.1681/ASN.2005111185](https://doi.org/10.1681/ASN.2005111185). [PubMed: 16597685].
6. Kolek OI, Hines ER, Jones MD, LeSueur LK, Lipko MA, Kiela PR, et al. 1alpha,25-Dihydroxyvitamin D3 upregulates FGF23 gene expression in bone: the final link in a renal-gastrointestinal-skeletal axis that controls phosphate transport. *Am J Physiol Gastrointest Liver Physiol.* 2005;**289**(6):G1036-42. doi: [10.1152/ajpgi.00243.2005](https://doi.org/10.1152/ajpgi.00243.2005). [PubMed: 16020653].
7. Liu S, Gupta A, Quarles LD. Emerging role of fibroblast growth factor 23 in a bone-kidney axis regulating systemic phosphate homeostasis and extracellular matrix mineralization. *Curr Opin Nephrol Hypertens.* 2007;**16**(4):329-35. doi: [10.1097/MNH.0b013e3281ca6ffd](https://doi.org/10.1097/MNH.0b013e3281ca6ffd). [PubMed: 17565275].
8. Bergwitz C, Juppner H. FGF23 and syndromes of abnormal renal phosphate handling. *Adv Exp Med Biol.* 2012;**728**:41-64. doi: [10.1007/978-1-4614-0887-1_3](https://doi.org/10.1007/978-1-4614-0887-1_3). [PubMed: 22396161].
9. Lamberts SW, de Herder WW, van der Lely AJ. Pituitary insufficiency. *Lancet.* 1998;**352**(9122):127-34. [PubMed: 9672293].
10. Beck L, Tenenhouse HS, Meyer RA, Meyer MH, Biber J, Murer H. Renal expression of Na⁺-phosphate cotransporter mRNA and protein: effect of the Gy mutation and low phosphate diet. *Pflugers Arch.* 1996;**431**(6):936-41. [PubMed: 8927512].
11. Carpenter TO. The expanding family of hypophosphatemic syndromes. *J Bone Miner Metab.* 2012;**30**(1):1-9. doi: [10.1007/s00774-011-0340-2](https://doi.org/10.1007/s00774-011-0340-2). [PubMed: 22167381].
12. Melmed S, Polonsky K, Larsen PR, Kronenberg HM. William's Textbook of Endocrinology. 12 ed. Philadelphia (USA): Elsevier Saunders; 2011.

13. Baroncelli GI, Toschi B, Bertelloni S. Hypophosphatemic rickets. *Curr Opin Endocrinol Diabetes Obes.* 2012;**19**(6):460-7. doi: [10.1097/MED.0b013e328358be97](https://doi.org/10.1097/MED.0b013e328358be97). [PubMed: [23108197](https://pubmed.ncbi.nlm.nih.gov/23108197/)].
14. Gaucher C, Walrant-Debray O, Nguyen TM, Esterle L, Garabedian M, Jehan F. PHEX analysis in 118 pedigrees reveals new genetic clues in hypophosphatemic rickets. *Hum Genet.* 2009;**125**(4):401-11. doi: [10.1007/s00439-009-0631-z](https://doi.org/10.1007/s00439-009-0631-z). [PubMed: [19219621](https://pubmed.ncbi.nlm.nih.gov/19219621/)].
15. Kinoshita Y, Saito T, Shimizu Y, Hori M, Taguchi M, Igarashi T, et al. Mutational analysis of patients with FGF23-related hypophosphatemic rickets. *Eur J Endocrinol.* 2012;**167**(2):165-72. doi: [10.1530/EJE-12-0071](https://doi.org/10.1530/EJE-12-0071). [PubMed: [22577109](https://pubmed.ncbi.nlm.nih.gov/22577109/)].
16. Rowe PS. The wrickkened pathways of FGF23, MEPE and PHEX. *Crit Rev Oral Biol Med.* 2004;**15**(5):264-81. [PubMed: [15470265](https://pubmed.ncbi.nlm.nih.gov/15470265/)].
17. Martin A, Liu S, David V, Li H, Karydis A, Feng JQ, et al. Bone proteins PHEX and DMP1 regulate fibroblastic growth factor Fgf23 expression in osteocytes through a common pathway involving FGF receptor (FGFR) signaling. *FASEB J.* 2011;**25**(8):2551-62. doi: [10.1096/fj.10-177816](https://doi.org/10.1096/fj.10-177816). [PubMed: [21507898](https://pubmed.ncbi.nlm.nih.gov/21507898/)].
18. Santos F, Fuente R, Mejia N, Mantecon L, Gil-Pena H, Ordonez FA. Hypophosphatemia and growth. *Pediatr Nephrol.* 2013;**28**(4):595-603. doi: [10.1007/s00467-012-2364-9](https://doi.org/10.1007/s00467-012-2364-9). [PubMed: [23179196](https://pubmed.ncbi.nlm.nih.gov/23179196/)].
19. Gattineni J, Baum M. Regulation of phosphate transport by fibroblast growth factor 23 (FGF23): implications for disorders of phosphate metabolism. *Pediatr Nephrol.* 2010;**25**(4):591-601. doi: [10.1007/s00467-009-1273-z](https://doi.org/10.1007/s00467-009-1273-z). [PubMed: [19669798](https://pubmed.ncbi.nlm.nih.gov/19669798/)].
20. Rowe PS. Regulation of bone-renal mineral and energy metabolism: the PHEX, FGF23, DMP1, MEPE ASARM pathway. *Crit Rev Eukaryot Gene Expr.* 2012;**22**(1):61-86. [PubMed: [22339660](https://pubmed.ncbi.nlm.nih.gov/22339660/)].
21. Fukumoto S, Shimizu Y. Fibroblast growth factor 23 as a phosphotropic hormone and beyond. *J Bone Miner Metab.* 2011;**29**(5):507-14. doi: [10.1007/s00774-011-0298-0](https://doi.org/10.1007/s00774-011-0298-0). [PubMed: [21822586](https://pubmed.ncbi.nlm.nih.gov/21822586/)].
22. Petersen DJ, Boniface AM, Schranck FW, Rupich RC, Whyte MP. X-linked hypophosphatemic rickets: a study (with literature review) of linear growth response to calcitriol and phosphate therapy. *J Bone Miner Res.* 1992;**7**(6):583-97. doi: [10.1002/jbmr.5650070602](https://doi.org/10.1002/jbmr.5650070602). [PubMed: [1414477](https://pubmed.ncbi.nlm.nih.gov/1414477/)].
23. Borghi MM, Coates V, Omar HA. Evaluation of stature development during childhood and adolescence in individuals with familial hypophosphatemic rickets. *ScientificWorldJournal.* 2005;**5**:868-73. doi: [10.1100/tsw.2005.102](https://doi.org/10.1100/tsw.2005.102). [PubMed: [16244755](https://pubmed.ncbi.nlm.nih.gov/16244755/)].
24. Huiming Y, Chaomin W. Recombinant growth hormone therapy for X-linked hypophosphatemia in children. *Cochrane Database Syst Rev.* 2005(1):CD004447. doi: [10.1002/14651858.CD004447.pub2](https://doi.org/10.1002/14651858.CD004447.pub2). [PubMed: [15674949](https://pubmed.ncbi.nlm.nih.gov/15674949/)].
25. Saggese G, Baroncelli GI, Bertelloni S, Perri G. Long-term growth hormone treatment in children with renal hypophosphatemic rickets: effects on growth, mineral metabolism, and bone density. *J Pediatr.* 1995;**127**(3):395-402. [PubMed: [7658269](https://pubmed.ncbi.nlm.nih.gov/7658269/)].
26. Reusz GS, Miltenyi G, Stubnya G, Szabo A, Horvath C, Byrd DJ, et al. X-linked hypophosphatemia: effects of treatment with recombinant human growth hormone. *Pediatr Nephrol.* 1997;**11**(5):573-7. [PubMed: [9323282](https://pubmed.ncbi.nlm.nih.gov/9323282/)].
27. Aono Y, Yamazaki Y, Yasutake J, Kawata T, Hasegawa H, Urakawa I, et al. Therapeutic effects of anti-FGF23 antibodies in hypophosphatemic rickets/osteomalacia. *J Bone Miner Res.* 2009;**24**(11):1879-88. doi: [10.1359/jbmr.090509](https://doi.org/10.1359/jbmr.090509). [PubMed: [19419316](https://pubmed.ncbi.nlm.nih.gov/19419316/)].
28. Gat-Yablonski G, Lazar L, Bar M, de Vries L, Weintrob N, Phillip M. Growth without growth hormone and similar dysmorphic features in three patients with sporadic combined pituitary hormone deficiencies. *Horm Res.* 2009;**72**(5):302-9. doi: [10.1159/000245932](https://doi.org/10.1159/000245932). [PubMed: [19844116](https://pubmed.ncbi.nlm.nih.gov/19844116/)].
29. Romero CJ, Nesi-Franca S, Radovick S. The molecular basis of hypopituitarism. *Trends Endocrinol Metab.* 2009;**20**(10):506-16. doi: [10.1016/j.tem.2009.06.005](https://doi.org/10.1016/j.tem.2009.06.005). [PubMed: [19854060](https://pubmed.ncbi.nlm.nih.gov/19854060/)].
30. Liapi C, Ginisty D, Chaussain JL, Job JC. [Tooth and face abnormalities associated with pituitary growth hormone insufficiency]. *Arch Fr Pediatr.* 1985;**42**(10):829-33. [PubMed: [3833098](https://pubmed.ncbi.nlm.nih.gov/3833098/)].
31. Kjellberg H, Beiring M, Albertsson Wikland K. Craniofacial morphology, dental occlusion, tooth eruption, and dental maturity in boys of short stature with or without growth hormone deficiency. *Eur J Oral Sci.* 2000;**108**(5):359-67. [PubMed: [11037751](https://pubmed.ncbi.nlm.nih.gov/11037751/)].
32. Kjellberg H, Wikland KA. A longitudinal study of craniofacial growth in idiopathic short stature and growth hormone-deficient boys treated with growth hormone. *Eur J Orthod.* 2007;**29**(3):243-50. doi: [10.1093/ejo/cjm005](https://doi.org/10.1093/ejo/cjm005). [PubMed: [17513878](https://pubmed.ncbi.nlm.nih.gov/17513878/)].
33. Bevis RR, Hayles AB, Isaacson RJ, Sather AH. Facial growth response to human growth hormone in hypopituitary dwarfs. *Angle Orthod.* 1977;**47**(3):193-205. [PubMed: [197861](https://pubmed.ncbi.nlm.nih.gov/197861/)].
34. Takahashi Y. Essential roles of growth hormone (GH) and insulin-like growth factor-I (IGF-I) in the liver. *Endocr J.* 2012;**59**(11):955-62. [PubMed: [22986486](https://pubmed.ncbi.nlm.nih.gov/22986486/)].
35. Stanley T. Diagnosis of growth hormone deficiency in childhood. *Curr Opin Endocrinol Diabetes Obes.* 2012;**19**(1):47-52. doi: [10.1097/MED.0b013e32834ec952](https://doi.org/10.1097/MED.0b013e32834ec952). [PubMed: [22157400](https://pubmed.ncbi.nlm.nih.gov/22157400/)].
36. Growth Hormone Research S. Consensus guidelines for the diagnosis and treatment of growth hormone (GH) deficiency in childhood and adolescence: summary statement of the GH Research Society. GH Research Society. *J Clin Endocrinol Metab.* 2000;**85**(11):3990-3. doi: [10.1210/jcem.85.11.6984](https://doi.org/10.1210/jcem.85.11.6984). [PubMed: [11095419](https://pubmed.ncbi.nlm.nih.gov/11095419/)].
37. Tauber M, Moulin P, Pienkowski C, Jouret B, Rochiccioli P. Growth hormone (GH) retesting and auxological data in 131 GH-deficient patients after completion of treatment. *J Clin Endocrinol Metab.* 1997;**82**(2):352-6. doi: [10.1210/jcem.82.2.3726](https://doi.org/10.1210/jcem.82.2.3726). [PubMed: [9024217](https://pubmed.ncbi.nlm.nih.gov/9024217/)].
38. Gasco V, Corneli G, Beccuti G, Prodam F, Rovere S, Bellone J, et al. Retesting the childhood-onset GH-deficient patient. *Eur J Endocrinol.* 2008;**159** Suppl 1:S45-52. doi: [10.1530/EJE-08-0293](https://doi.org/10.1530/EJE-08-0293). [PubMed: [18805914](https://pubmed.ncbi.nlm.nih.gov/18805914/)].
39. Hou JW. Amelioration of hypophosphatemic rickets and osteoporosis with pamidronate and growth hormone in Lowe syndrome. *J Formos Med Assoc.* 2009;**108**(9):730-5. doi: [10.1016/S0929-6646\(09\)60397-1](https://doi.org/10.1016/S0929-6646(09)60397-1). [PubMed: [19773212](https://pubmed.ncbi.nlm.nih.gov/19773212/)].