



COVID-19 Complicated by Massive Acute Pulmonary Embolism: A Case Report

Manouchehr Hekmat ¹, Zahra Ansari Aval ^{2,*}, Alireza Omid Farzin ¹, Ali Dabbagh ³, S. Adeleh Mirjafari ⁴ and Hamid Ghaderi ¹

¹Department of Cardiovascular Surgery, Shahid Modarres Hospital, Shahid Beheshti University of Medical Sciences, Tehran, Iran

²Clinical Research and Development Center at Shahid Modarres Hospital, Department of Cardiac Surgery, Shahid Beheshti University of Medical Sciences, Tehran, Iran

³Department of Anesthesiology, Shahid Modarres Hospital, Shahid Beheshti University of Medical Sciences, Tehran, Iran

⁴Department of Pediatrics, Ali-Asghar Children's Hospital, Iran University of Medical Sciences, Tehran, Iran

*Corresponding author: Department of Cardiovascular Surgery, Shahid Modarres Hospital, Shahid Beheshti University of Medical Sciences, Saadat Abad, P. O. Box 1998734383, Tehran, Iran. Tel: +98-2122083106, Fax: +98-2122074101, Email: zahraansariaval@gmail.com

Received 2020 May 31; Accepted 2020 June 20.

Abstract

Introduction: COVID-19 is an emerging disease that has been spread all over the world. Not all the dimensions and manifestations of the disease have yet been fully explored. One such manifestation is vascular thrombosis that occurs in the lungs and other vessels. However, it is often ignored or mistaken for pulmonary manifestations. Herein, we presented a case with dominant pulmonary embolism manifestations. The COVID-19 symptoms were detected in the patient a few days after heart surgery, and he was appropriately treated and discharged.

Case Presentation: The patient was a 62-year-old man visiting with the signs and symptoms of pulmonary embolism. In the CT-angiography, massive pulmonary embolism was reported in the right and left pulmonary arteries of the patient. Moreover, the patient's echocardiogram showed a clot in the right ventricle in addition to severe right ventricular dysfunction. The patient underwent emergency heart surgery to remove the clot. In the 3 - 4 postoperative days, the pulmonary manifestations of COVID-19 emerged. The throat swab test was positive for COVID-19, and the patient received treatment. After receiving appropriate treatments for about two weeks, the patient was discharged with good general health.

Conclusions: The presented case had the primary pulmonary embolism symptoms. However, in the 2 - 3 postoperative days, he showed the COVID-19 symptoms and received treatment. Pulmonary embolism can be a manifestation of COVID-19.

Keywords: COVID-19, SARS-CoV-2, Coronavirus, Pulmonary Embolism, Cardiac Surgery, Survival

1. Introduction

COVID-19, which is officially referred to as the Novel Coronavirus 2019 (NCoV2019), usually manifests itself as viral pneumonia (1). Acute pulmonary embolism (PE) is one of the causes of the deterioration of viral pneumonia (2). The hallmark of patients with severe COVID-19 is coagulopathy (3, 4), and 71.4% of deceased patients meet the IHTH criteria for disseminated intravascular coagulation (DIC) (4). Recent research articles have demonstrated an increased tendency to coagulation (with an increased level of D-Dimer and Fibrinogen) (4, 5).

In the literature, there is a limited description of COVID-19 and venous thromboembolism (VTE) comorbidity (6, 7), and there are few studies on the association of COVID-19 with PE (3, 6, 8-10). All the published cases have had segmental and sub-segmental PE (6, 8-10). The patient presented here was the first reported case of COVID-19 and

bilateral massive pulmonary thromboembolism comorbidity. The patient received medical therapy and underwent open-heart surgery, and the embolism was removed. Finally, he was discharged with a good general health status and no complications. None of the other cases published so far has presented any information on the outcome of treatments, patients' survival or discharge, or the outcome of the simultaneous treatment of COVID-19 and PE.

2. Case Presentation

The patient was a 62-year-old man with progressive dyspnea for a week before visiting the emergency department of a hospital in Rasht City, Gilan Province, Iran. He underwent echocardiography in the hospital, and then, he was referred to Modarres Hospital, Tehran, upon the diagno-

sis of a large right ventricular clot (in echo) and D-Dimer = 965 mg/dL, and due to the risk of pulmonary embolism. Modarres Hospital is a referral and teaching hospital affiliated with the Shahid Beheshti University of Medical Sciences.

The patient experienced coughs and fatigue for about five days but had no fever, rhinorrhea, or headache.

At the time of admission, his body temperature was 37.2°C, and his O₂ saturation was 86% on room air. His vital signs were as follows: HR = 120 Bpm, BP = 60.90 mm Hg, and RR = 24.

The patient had not recently traveled, and also, had not reported any history of diabetes or hypertension. One month before, he had intracranial hemorrhage (ICH) and underwent craniotomy. He had been treated with Xalaban and ASA before the craniotomy.

Laboratory tests at the time of admission showed WBC = 12000 per mL, lymph = 7.13%, LDH = 829 u/L, CRP = 2+, ESR = 40 mm/h, PT = 3.15, PTT = 33, and INR = 2.21. Due to the progressive nature of the respiratory symptoms, the computed tomography and CT angiography (CTA) of pulmonary veins were performed. CTA revealed massive pulmonary embolism at the beginning of the left and right pulmonary arteries, and compatible pneumonia presentation was observed (Figure 1).

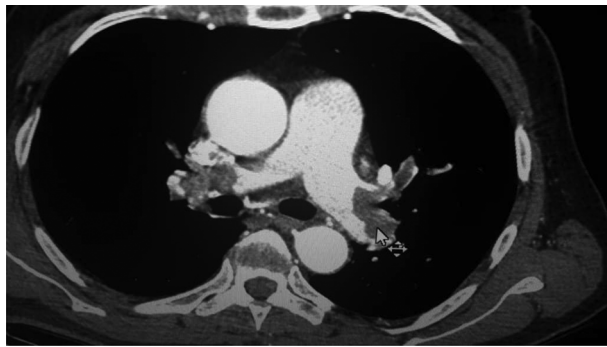


Figure 1. The CT angiography of the patient with pulmonary embolism; embolism is observed in the both left and right pulmonary arteries.

Echocardiography showed a large RV mass, PAP = 53 mmHg, and severe RV dysfunction. The patient was deemed to be a candidate for surgical embolectomy. Emergency angiography was performed, revealing a mild coronary artery disease. A Doppler ultrasound of the lower limbs yielded normal results, with no finding supporting deep vein thrombosis (DVT). Moreover, neurological observation and a brain CT scan were performed with normal results. At the time of entering the operating room, the patient had O₂ saturation = 88% and received an average dose of adrenaline inotrope.

Under sterile conditions and after prep and drape, the patient underwent midsternotomy under general anesthesia and endotracheal intubation. The pericardium was opened, and the heart was exposed. The right ventricle dilated, and the pulmonary arterial pressure significantly increased. Afterward, heparin was injected, purse-string sutures were tied on the heart, the aorta, SVC, and IVC were cannulated, cardiopulmonary bypass was established, the temperature was reduced, the aorta was clamped, and Del Nido cardioplegia solution was injected. Subsequently, the heart was arrested, and the right atrium was opened. A large clot was observed inside the right atrium and ventricle, which was fully mobile and completely protruded inside the right ventricle. Next, the mass was completely removed, and there was no patent foramen ovale (PFO). Then, an incision was made on the main pulmonary artery. The interior of the left and right pulmonary arteries was explored, and they were found to be filled with clots, which were removed (Figure 2). Subsequently, the pulmonary artery was repaired in two layers. Warming and deairing were performed and the aorta was declamped, helping the heart to gradually and automatically start beating. Next, the wall of the right atrium was repaired, and the patient was disconnected from the cardio-pulmonary bypass using an inotrope. The patient had paroxysmal atrial tachycardia (PAT) twice and received defibrillation. Afterward, sternum wiring was performed, and the patient was delivered to the heart surgery ICU with stable hemodynamics and after receiving inotrope (a high dose of adrenaline and noradrenaline) and milrinone support.

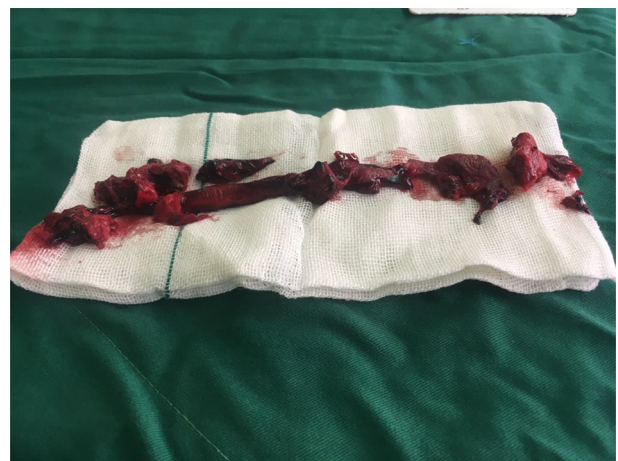

Figure 2. Thromboembolism removed from the left and right pulmonary arteries by heart surgery

Gradually, in the next 48 - 72 hours, the medications were tapered off, and the patient was weaned from the ven-

tilator and connected to the BiPAP machine. Postoperative echocardiography still showed severe RV dysfunction, and pulmonary pressure was still high. On postoperative day 5, the patient developed fever (39 - 39.5°C) with a loss of muscle strength in all limbs. Moreover, lymphopenia was reported in lab tests (WBC = 600/ML and Lymph = 10%). The patient was once again intubated (postoperative day 6). A throat swab COVID-19 test was ordered for the real-time fluorescence polymerase chain reaction (RT.PCR) method. Antibiotic regimen was boosted, hydroxychloroquine was started, and a repeat CT scan was performed. CT scan images suggested pulmonary involvement like pneumonia or COVID-19, and massive bilateral pleural effusion was observed. Sobilateral chest tubes were placed. The COVID-19 test result was reported positive 48 hours after sending the throat swab sample to the lab. The patient was intubated for 48 hours and then, extubated. A CT scan was performed for the third time and showed viral pneumonia symptoms. The patient was kept at the ICU for 72 hours after the repeated extubation. The anticoagulant was changed from heparin to warfarin, and then, the patient was transferred to the COVID-19 ward. He was monitored in the ward for three days. Respiratory symptoms were significantly mitigated, and the patient was discharged with a good health status and prescribed medications. The patient visited the clinic two weeks after discharge for follow-up and had a good health status.

3. Discussion

Patients with COVID-19 often show respiratory signs, which make it difficult to differentiate COVID-19 from PE in severe cases or comorbidities. COVID-19 may predispose patients to both arterial and venous thromboembolic events due to an increased level of inflammatory reactions, hypoxia, immobility, and DIC (9). The comorbidity of PE and COVID-19 confuses the emergency department personal. Their comorbidity overlaps the clinical signs of these two clinical manifestations. The diagnosis of COVID-19 pneumonia is confirmed with the RT.PCR and the presence of typical findings in the CT scan (11, 12). However, pulmonary embolism is more difficult to confirm. The reason is that the pro-inflammatory and hypercoagulability agents determined by lactate dehydrogenase, ferritin, C-reactive protein, and interleukins level increase in patients with COVID-19 (5, 13).

Recent articles have shown that patients with COVID-19 are likely to experience an increased level of D-dimer as well as fibrinogen and fibrin degradation products (4, 5). An increased level of D-dimer is observed in patients with COVID-19, even in the absence of pulmonary embolism (13).

An increase in D-dimer > 1 mg/dL may be a predictor of mortality in these patients but is not specific in VTE diagnosis (14, 15). As a result, CT angiography greatly helps VTE diagnosis.

In the present case, the D-dimer level was extremely high, which can be attributed to his dominant thromboembolic manifestations. The overlap caused by changes in the lungs makes it difficult or even impossible to differentiate embolism from viral pneumonia.

A study in the Netherlands on 184 patients with COVID-19 admitted to the ICU showed that 25 cases had PE (segmental arteries were involved in 18 cases, and sub-segmental arteries were involved in seven cases) (9). In the mentioned study, none of the patients had clinical signs, and all the patients underwent a VTE examination.

However, the first symptomatic cases of pulmonary embolism were two patients from Wuhan, China, with COVID-19 signs, as reported by Xie et al. These two patients were 57 and 70 years old. A repeat pulmonary CT scan was performed on days seven and 10 of hospitalization due to the deterioration of respiratory signs, and embolism was observed in the lobar pulmonary and sub-segmental arteries (6). The article did not mention the patients' survival or death.

Cellina et al. (8) reported a 60-year-old man with COVID-19 in Italy, who underwent a CT scan due to the deterioration of respiratory signs. After CTA, a thrombosis was found in the left pulmonary artery and the right intra-lobar artery (8). They did not mention the outcome of the treatment.

Moreover, Casey et al. from San Diego reported a 42-year-old man with COVID-19 and with no risk factors. CTA revealed bilateral segmental pulmonary embolism (10). Similar to the previous study, they did not mention the outcome of the treatment.

3.1. Conclusion

In patients with COVID-19 who show progressive respiratory signs, the chance of comorbid PE must be taken into account, and CT angiography should be performed to show if there is acute superimposed pulmonary embolism. In the case of massive PE, it is recommended that treatment occurs simultaneously with medical or heart surgery to remove the clots. Moreover, it is suggested to start treatment with a prophylactic dose of an anticoagulant in high-risk COVID-19 patients.

Acknowledgments

We hereby thank all the anonymous doctors, nurses, and medical staff who are sacrificing their lives for treat-

ing patients with COVID-19, especially the personnel of Tehran's Modarres Hospital.

Footnotes

Authors' Contribution: Manouchehr Hekmat was the head of the surgical team who managed this complication. Zahra Ansari Aval, Alireza Omid, and Hamid Ghaderi were members of the surgical team, who also helped in the data collection procedure. Ali Dabbagh was the head of the anesthesiology team. S. Adeleh Mirjafari was a major contribution in searching the literature and preparing the discussion. Hamid Ghaderi drafted the manuscript and provided administrative, technical, and material support. All the authors edited the final draft and approved the final version of the manuscript.

Conflict of Interests: The authors declare that they have no competing interests related to the manuscript.

Ethical Approval: 121111

Funding/Support: The authors declare that they have received no funding.

Informed Consent: Written informed consent was obtained from the patient for publication of this case and accompanying images.

References

- Jolobe OM. Similarities Between Community-Acquired Pneumonia and Pulmonary Embolism. *The American Journal of Medicine*. 2019;**132**(12). e863.
- Alirezaei T, Aval ZA. Rescue thrombolysis partial failure in massive PE complicated with in-transit thrombus. *International medical case reports journal*. 2019;**12**:9-14.
- Wang J, Hajizadeh N, Moore EE, McIntyre RC, Moore PK, Veress LA, et al. Tissue plasminogen activator (tpa) treatment for COVID-19 associated acute respiratory distress syndrome (ARDS): a case series. *Journal of thrombosis and haemostasis*. 2020.
- Tang N, Bai H, Chen X, Gong J, Li D, Sun Z. Anticoagulant treatment is associated with decreased mortality in severe coronavirus disease 2019 patients with coagulopathy. *Journal of Thrombosis and Haemostasis*. 2020;**18**(5):1094-9.
- Han H, Yang L, Liu R, Liu F, Wu K, Li J, et al. Prominent changes in blood coagulation of patients with SARS-CoV-2 infection. *Clinical Chemistry and Laboratory Medicine (CCLM)*. 2020;**1**(ahead-of-print).
- Xie Y, Wang X, Yang P, Zhang S. COVID-19 complicated by acute pulmonary embolism. *Radiology: Cardiothoracic Imaging*. 2020;**2**(2). e200067.
- Danzi GB, Loffi M, Galeazzi G, Gherbesi E. Acute pulmonary embolism and COVID-19 pneumonia: a random association? *European heart journal*. 2020.
- Cellina M, Oliva G. Acute pulmonary embolism in a patient with COVID-19 pneumonia. *Diagnostic and Interventional Imaging*. 2020.
- Klok FA, Kruip MJHA, Van der Meer NJM, Arbous MS, Gommers DAMP, Kant KM, et al. Confirmation of the high cumulative incidence of thrombotic complications in critically ill ICU patients with COVID-19: An updated analysis. *Thrombosis research*. 2020.
- Casey K, Itean A, Nicolini R, Auten J. COVID-19 pneumonia with hemoptysis: Acute segmental pulmonary emboli associated with novel coronavirus infection. *The American Journal of Emergency Medicine*. 2020;**3**-6,7.
- Chung M, Bernheim A, Mei X, Zhang N, Huang M, Zeng X, et al. CT imaging features of 2019 novel coronavirus (2019-nCoV). *Radiology*. 2020;**295**(1):202-7.
- Lei J, Li J, Li X, Qi X. CT imaging of the 2019 novel coronavirus (2019-nCoV) pneumonia. *Radiology*. 2020;**295**(1):18.
- Chen J, Wang X, Zhang S, Liu B, Wu X, Wang Y, et al. Findings of acute pulmonary embolism in COVID-19 patients. *SSRN*. 2020.
- Wang D, Hu B, Hu C, Zhu F, Liu X, Zhang J, et al. Clinical characteristics of 138 hospitalized patients with 2019 novel coronavirus-infected pneumonia in Wuhan, China. *Jama*. 2020;**323**(11):1061-9.
- Zhou F, Yu T, Du R, Fan G, Liu Y, Liu Z, et al. Clinical course and risk factors for mortality of adult inpatients with COVID-19 in Wuhan, China: a retrospective cohort study. *The lancet*. 2020;**395**(10229):1054-62.