



Disseminated Intravascular Coagulation as the First Manifestation of Coronavirus Disease: Report of a Survived Deadly Case

Arezoo Esmailzadeh¹, Shahla Chaichian^{2,*}, Abolfazl Mehdizadehkashi¹, Kobra Tahermanesh¹, Samaneh Rokhgireh¹, Nastaran Khodakarim³, Shima Ghafourian⁴, Saeedeh Moslemi¹ and Meisam Akhlaghdoust⁵

¹ Endometriosis Research Center, Iran University of Medical Sciences, Tehran, Iran

² Pars Advanced and Minimally Invasive Medical Manners Research Center, Pars Hospital, Iran University of Medical Sciences, Tehran, Iran

³ Department of Medical Oncology and Hematology, Iran University of Medical Sciences, Tehran, Iran

⁴ Department of Radiology, Iran University of Medical Sciences, Tehran, Iran

⁵ Functional Neurosurgery Research Center, Shahid Beheshti University of Medical Sciences, Tehran, Iran

* **Corresponding author:** Shahla Chaichian, Pars Advanced and Minimally Invasive Medical Manners Research Center, Pars Hospital, Iran University of Medical Sciences, Tehran, Iran. Tel: +989121303526; Email: shchaichian@gmail.com

Received 2020 August 01; Revised 2020 August 13; Accepted 2020 August 14.

Abstract

Introduction: Coronavirus disease 2019 (COVID-19), newly emerging in the world as a pandemic disease, can have rare extrapulmonary manifestations. Few studies have reported coagulation disorders, induced by coronavirus; however, hemorrhage is an extremely rare and life-threatening phenomenon in COVID-19.

Case Presentation: Herein, we present a 31-year-old woman referring with vaginal bleeding, melena, skin ecchymosis, mucosal bleeding, melena, hematuria, and hypovolemic shock. At our center, she was diagnosed as a case of severe internal hemorrhage due to ovulation site hemorrhage and underwent emergency surgery, complicated by prolonged international normalized ratio, which could be due to the presence of COVID-19 in the patient, detected by spiral computed tomography.

Conclusion: This case showed the importance of examining COVID-19 in any patients referring to the hospital during the pandemic as well as paying greater attention to the effect of COVID-19 on coagulation disorders in these patients.

Keywords: Blood coagulation disorders, COVID-19, Coronavirus, Disseminated intravascular coagulation

1. Introduction

Coronavirus disease 2019 (COVID-19), announced by the World Health Organization as a pandemic respiratory disease in March 2020, is considered a critical health issue today. The COVID-19 has infected more and more individuals worldwide and caused more than 280,000 mortalities around the globe (at the time of writing this paper), without any approved treatments or vaccination to date (1). The COVID-19 may present with mild symptoms, such as fever, headache, cough, shortness of breath, fatigue, malaise or severe pneumonia, multiple organ failure (MOF), and mortality (2).

The COVID-19 may have a long incubation period, up to 14 days, and can be tremendously infectious during this period (3). Therefore, clinical symptoms are not sufficient for diagnosis, and laboratory tests are required for screening and definite diagnosis of COVID-19, including reverse transcription polymerase chain reaction (RT-PCR), chest computed tomography (CT) scan, and serum antibody tests (4).

The COVID-19 can impair the function of several organs and respiratory system, which can cause severe complications for the patient, worsen the patient prognosis, and result in mortality (5). One of the important predictors of COVID-19 mortality is the development of coagulopathy in the patients (6) that

can cause severe problems for the patients, such as thrombosis and hemostasis, or life-threatening conditions, such as disseminated intravascular coagulation (DIC), observed in the majority of COVID-19 nonsurvivors (6, 7). The DIC is an acquired condition, resulting from the consumption of coagulation factors that can cause fibrin clots and disseminated coagulation leading to MOF and mortality (8). Therefore, it is necessary to measure D-dimer, prothrombin time (PT), fibrinogen, and platelet count in patients with COVID-19 (7).

Herein, we report a complicated case of COVID-19, presenting with ovulation site hemorrhage undergoing emergent surgery; however, it was complicated with prolonged international normalized ratio (INR) levels, elevated D-dimer levels, thrombocytopenia, and lymphopenia and survived by appropriate and on time management. This case draws the physicians' attention to be aware of the coagulopathies and risk of DIC in patients with COVID-19.

2. Case Presentation

A 31-year old woman, G₁Ab₁, with a history of spontaneous abortion 3 months ago and regular menses was transferred to a tertiary teaching hospital by Emergency Medical Services complaining of faint and severe dizziness. On arrival, she was ill,

but not toxic with the Glasgow Coma Scale (GCS) of 11/15. Her spouse reported a 3-day history of vaginal bleeding, melena, hematuria, skin ecchymosis, and mucosal bleeding, aggravated since the previous day, finally resulted in faint and referral to the hospital. The patient had a positive history of appendectomy and ovarian cystectomy a year ago and multiple surgical uncomplicated procedures due to a car accident, mainly on the limbs, several months ago. Quick clinical screening questions were negative for COVID-19 (i.e., cough, fever, malaise, headache, and dyspnea).

On physical examination, the blood pressure (BP), respiratory rate, and pulse rate (PR) were reported as 60 mmHg/pulse, 32 breaths/min, and 140 beats/minute, respectively. The radial pulse was not palpable, and the jugular pulse was hardly palpable. Her limbs were pale and cold, and conjunctiva was pale, but not icteric. The cardiopulmonary auscultation seemed unremarkable with tachycardia. On abdominal examination, the abdomen had guarding without tenderness or rebound tenderness (not reliable due to the low GCS).

The patient had active vaginal bleeding. As the venous lines were not functional, a central venous catheter was inserted for the patient, and the blood sample was sent for the measurement of complete blood count, beta-human chorionic gonadotropin (β -hCG), coagulation factors, and RT-PCR of COVID-19. After rapid infusion of 1000 cc of a crystalloid solution, 3 U of packed cells (without crossmatch) and 2 U of fresh frozen plasma (FFP) were infused. Focused Assessment with Ultrasound for Trauma scan was immediately performed in the emergency department indicating intra-abdominal fluid accumulation (more than 2 L). The baseline serum level of hemoglobin and INR were 5.1 mg/dl and 2.8, respectively.

After resuscitation, she was quickly transferred to the operating room (OR), and after confirming internal hemorrhage (probably due to ovarian hemorrhagic cyst) by portable ultrasound at OR and approving negative β -hCG, the patient underwent general anesthesia. According to the hospital's protocol on the laparoscopic ban for surgical procedures with unknown etiologies at the time of the COVID-19 pandemic, midline abdominal incision was performed. Moreover, 2,750 cc blood and 250 cc clot were suctioned.

During comprehensive abdominal exploration, the right ovary was perforated at the ovulation site with active bleeding. Hemostasis was meticulously performed by 3-0 Vicryl suture. The abdomen was washed with 1 L of warm normal saline. After ensuring sufficient hemostasis, the Jackson-Pratt drain was placed, and the peritoneum was closed with 2-0 Vicryl suture. In addition, the fascia was repaired with 0 Nylon suture. After hemostasis of subcutaneous tissue, the incision was closed by 3-0 separate Nylon sutures with specific attention to

maximum tissue hemostasis. After wound repair, compression dressing was performed.

At the end of the surgery, urinary output, BP, and PR were 500 cc, 138/80 mmHg, and 116 beats/min, respectively. Two extra units of crossmatched packed cell and 3 U of FFP were transfused at this time. The patient was transferred to the intensive care unit (ICU), and 10 U of platelets were requested from the Blood Transfusion Center. Meropenem was initiated at a dose of 1 g intravenously (IV) every 8 h. During the first 12 h after the surgery, 700 cc of the blood was collected from the drain bag; however, the amount of the blood in the bag reduced to 90 cc during the next 12 h. The patient INR was 5.02 after the surgery.

The day after the surgery, the patient had a serum calcium level of 7 mg/dl (reference value: 8.6-10.6 mg/dl); therefore, one vial of calcium gluconate was infused. The patient vital signs were stable, and her tachycardia (PR=120) decreased over the next few hours to 98 beats/min. The INR level reduced to 2.5, late that night. Two more units of FFP and 10 U of platelets were transfused. The next day, C-reactive protein (CRP) was > 48 mg/L (negative < 6 mg/l), and lactate dehydrogenase (LDH) was 757 U/L (reference value: 225-500 U/L). Furthermore, creatine phosphokinase was 364 IU/L (reference value: 24-195 U/L). On the next day, fever ($T=38^{\circ}\text{C}$) and intermittent coughs emerged. According to the novel COVID-19 pandemic and despite negative RT-PCR for COVID-19, a spiral chest high-resolution computed tomography (HRCT) scan was performed. The HRCT confirmed the diagnosis of COVID-19 by bilateral multifocal and multilobular ground-glass opacities and bilateral pleural effusion (Figure 1).

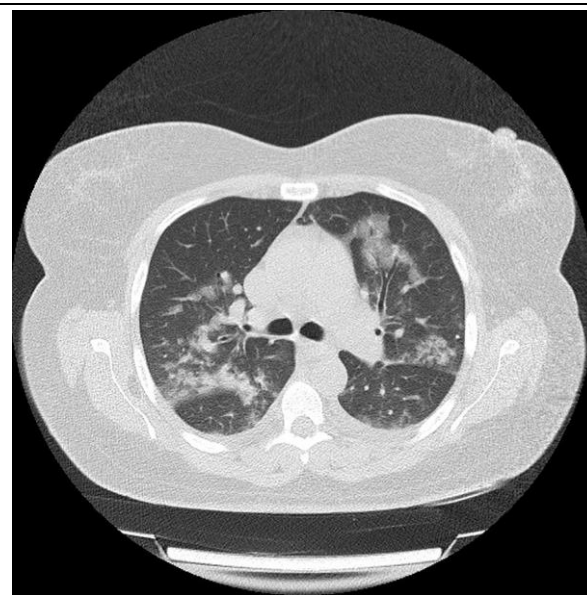


Figure 1. High-resolution computed tomography of patient at time of admission illustrating bilateral multifocal and multilobular ground-glass opacities with bilateral pleural effusion

After urgent consultation with infectious and pulmonary specialists, the patient was immediately transferred to COVID-19 specific ICU, and the treatment of COVID-19 was promptly started by the administration of sofosbuvir 400 mg daily, hydroxychloroquine 400 mg BID for the first day and then 200 mg BID, and 500 mg hydrocortisone IV stat. At this time, the INR level reached 5.2, and the PT level was 37.7 sec (reference value: 12-13 sec). Through repetition, the INR was 4.5, and the PT level was 61.5 sec. A few hours later, the ICU nurse reported active bleeding from the drain site. A compression dressing was placed on the bleeding site. Abdominal ultrasound was performed, which was unremarkable. The INR level raised to 7.8, and partial thromboplastin time was 70 sec (reference value: 25-45 sec). Moreover, fibrin degradation product (FDP) level reached 12 ng/ml (normal value <5 ng/ml).

By hematologic consultation, she received another 6 U of FFP and 2 U of NovoSeven (recombinant factor VII) with a 3-hour interval. Then, she received 2 U of packed cell and 2 more units of FFP, continued by a maintenance dose of 2 U/8 h. On the next morning, the patient INR and PT reduced to 1.3 and 15 sec, respectively. It seems that the recovery process was initiated at this stage. Clinical symptoms were ameliorated, and laboratory tests slowly returned to a normal range.

Two days after stopping the bleeding and fever, the INR values returned to the normal range. Furthermore, there was a reduction in patient cough and dyspnea and significant improvement of HRCT manifestations (Figure 2). Subsequently, the patient was transferred to the Corona-Specific (Royal) Ward. The patient was discharged from the hospital

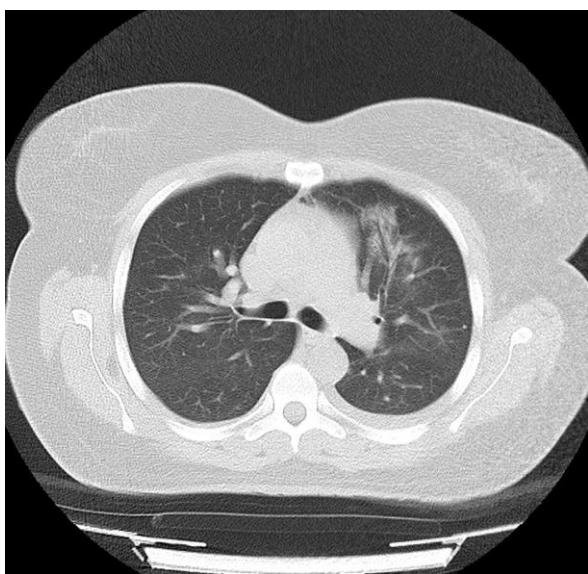


Figure 2. High-resolution computed tomography of patient after treatment illustrating significant improvement

following 2 days of stable condition (4 days after the resolution of the signs and symptoms). At discharge, the patient and her family members were directed to follow the standard quarantine orders and other physical distancing regulations. Returning to the hospital was recommended in case of any adverse symptoms, otherwise 2 weeks after discharge. According to the follow-up program in the study, she feels well with no recurrence to date.

The present study was approved by the Ethics Committee of Pars Advanced and Minimally Invasive Medical Manners Research Center, Pars Hospital, Tehran, Iran (code: 99G5019).

3. Discussion

Herein, we reported a young woman undergoing emergent surgery for the life-threatening ovulation site bleeding with the observation of prolonged INR, attributed to COVID-19, suspected by mild ordinary symptoms and diagnosed using a spiral chest CT scan after the surgery, despite the negative results of RT-PCR for COVID-19. This case has several important points to be noticed.

The first point is the recommendation to check COVID-19 infection in any patients referring to the hospital right after arrival (9). The consideration of this recommendation is necessary, as the clinical symptoms may not be present during the incubation period and are not sufficient for diagnosis (3). Nevertheless, this may have exceptions, including emergent patient conditions, such as in the present case, as it was required to perform an emergent surgery to save the patient life and there was no time wait for the result of COVID-19 RT-PCR, due to massive vaginal bleeding and unstable vital signs. Therefore, the surgery was performed after the evaluation of the patient by the universal clinical screening test that seems a good policy in the COVID-19 pandemic for patients with emergent conditions (10).

In such conditions, it is necessary to consider the suggested precautions for patient visitors and medical staff (11), before the exclusion of COVID-19. The present study also followed the hospital protocol on the laparoscopic ban for surgical procedures with unknown etiologies at the time of the COVID-19 pandemic, and open laparotomy was performed (12).

Another important point was the negative results of COVID-19 RT-PCR, which could be due to the low sensitivity of the available used RT-PCR kits. Nevertheless, due to the high LDH and CRP levels and mild clinical symptoms, including low-grade fever and intermittent coughs, HRCT was performed confirming the diagnosis of COVID-19. This finding confirms the results of a study conducted by Kasteren et al. on the low sensitivity of RT-PCR kits (13) and emphasizes the consideration of COVID-19 in any patients, even with negative RT-PCR results.

Furthermore, this result corroborates the results of a study carried out by Fang et al. on the higher sensitivity of HRCT, compared to that of RT-PCR (98% vs. 71%) (14).

Of note, the present case did not have severe clinical symptoms of COVID-19, and the mild symptoms could be relieved and considered postoperative complications. Mardani et al. have also suggested that severe persistent lymphopenia and high levels of serum CRP and LDH, observed in the current case, are associated with COVID-19 and can be used as predictors of positive COVID-19 (15). This result confirms the findings in the present patient and implies that during the COVID-19 pandemic, more attention should be given to the accurate diagnosis of COVID-19 in all patients with any clinical symptoms.

It is worth mentioning that the patient showed a rare and serious complication, as the first clinical manifestation, emphasizing the importance of appropriate diagnosis and management of COVID-19 complications. It has been previously reported that COVID-19 can predispose patients to DIC and venous thromboembolism, supposed to be due to excessive activation of the coagulation cascade and platelets (16). However, there have been few cases of bleeding reported in COVID-19 patients. Sharifi-Razavi et al. reported intracerebral hemorrhage in a 79-year-old man with a history of fever and cough (17).

Poyiadji et al. also reported acute hemorrhagic necrotizing encephalopathy in a young woman with a 3-day history of cough and fever (18). Hemorrhage in both of these cases was localized in the patient brain; nevertheless, the current case presented with bleeding at different sites, such as melena, skin ecchymosis, mucosal bleeding, and ovulation site hemorrhage, resulting in hypovolemic shock, requiring emergent surgical management. Furthermore, hemorrhage at different sites was the first manifestation, and the present patient did not have the common symptoms of COVID-19, such as cough or fever, before these presentations; however, the two previously reported cases had a history of cough and fever (17, 18).

Carvalho et al. reported gastrointestinal (GI) infection of COVID-19, with acute hemorrhagic colitis in a 71-year-old woman, presenting with diffuse abdominal pain, distension, and bloody diarrhea (19). This case resembled the current case, considering melena in our patient; nevertheless, the case presented by Carvalho et al. developed bloody diarrhea during GI presentation of COVID-19 and was treated with antimicrobial agents (19). Nonetheless, the current patient showed hemorrhage at different sites and required surgery due to hemorrhage in the ovulation site. Other similarities between this case and present case were the presentation of cough after the hemorrhage as well as the increased CRP level (19).

The prolonged INR, thrombocytopenia, and raised FDP complicated the patient conditions, and the case required several units of FFP, packed cell, platelet, and recombinant factor VII to survive. The patient had no underlying disease, and these complications were almost certainly related to COVID-19, supposed to be caused by the systemic inflammatory response to COVID-19 resulting in an imbalance between pro- and anti-coagulant homeostasis and dysregulated thrombin generation, both locally and systemically (16). Due to the importance of progression of coagulopathy into DIC, as a deadly condition, it is necessary to pay greater attention to the appropriate diagnosis of coagulation disorders in patients with COVID-19 by the measurement of D-dimer, PT, fibrinogen, and platelet count (7), as performed in the present study.

It has been previously reported that thrombocytopenia and D-dimer (6) are associated with severe COVID-19 and ICU admission. Due to the high mortality of patients with DIC and observation of DIC in 74% of nonsurvivors (6), some have suggested the treatment of all COVID-19 patients with a prophylactic dose of low-molecular-weight heparin in order to reduce the cytokine storm, coagulation dysfunction, MOF, and sepsis leading to the reduction of the mortality rate of patients with COVID-19 (20). Nevertheless, this approach is contraindicated in some patients, including those with active bleeding, low platelet count, or renal impairment. Consequently, the previously suggested guidelines could not be used, and close management was required for saving the patient life.

In conclusion, the present case showed that HRCT is necessary for the diagnosis of COVID-19, and RT-PCR and clinical symptoms are not sufficient for a definite diagnosis. Furthermore, this case demonstrated the importance of giving attention to severe complications that may occur in patients even before emerging ordinary symptoms of the disease that can cause serious problems for patients and make the management difficult. In the current case, the patient developed DIC and bleeding from different sites, without any introductory symptoms. Bleeding is a very rare complication associated with COVID-19, and further studies are required to outline the hemorrhagic sites in COVID-19, associated exact causes, and best approaches to the management.

Footnotes

Conflict of Interests: None declared.

References

1. World Health Organization. Coronavirus disease 2019 (COVID-19): situation report, 70. Geneva: World Health Organization; 2020.
2. Singhal T. A review of coronavirus disease-2019 (COVID-19). *Indian J Pediatr.* 2020;87(4):281-6. doi: [10.1007/s12098-020-](https://doi.org/10.1007/s12098-020-)

- 03263-6. [PubMed: 32166607].
3. Lauer SA, Grantz KH, Bi Q, Jones FK, Zheng Q, Meredith HR, et al. The incubation period of coronavirus disease 2019 (COVID-19) from publicly reported confirmed cases: estimation and application. *Ann Intern Med.* 2020;**172**(9):577-82. doi: [10.7326/M20-0504](https://doi.org/10.7326/M20-0504). [PubMed: 32150748].
 4. Poortahmasebi V, Zandi M, Soltani S, Jazayeri SM. Clinical Performance of RT-PCR and Chest CT Scan for Covid-19 Diagnosis; a Systematic Review. *Adv J Emerg Med.* 2020; **4**(2s):e57. doi: [10.22114/ajem.v4i2s.459](https://doi.org/10.22114/ajem.v4i2s.459).
 5. Nikpouraghdam M, Farahani AJ, Alishiri G, Heydari S, Ebrahimnia M, Samadinia H, et al. Epidemiological characteristics of coronavirus disease 2019 (COVID-19) patients in Iran: a single center study. *J Clin Virol.* 2020;**127**:104378. doi: [10.1016/j.jcv.2020.104378](https://doi.org/10.1016/j.jcv.2020.104378). [PubMed: 32353762].
 6. Tang N, Li D, Wang X, Sun Z. Abnormal coagulation parameters are associated with poor prognosis in patients with novel coronavirus pneumonia. *J Thromb Haemost.* 2020;**18**(4):844-7. doi: [10.1111/jth.14768](https://doi.org/10.1111/jth.14768). [PubMed: 32073213].
 7. Makatsariya AD, Grigoreva KN, Mingalimov MA, Bitsadze VO, Khizroeva JK, Tretyakova MV, et al. Coronavirus disease (COVID-19) and disseminated intravascular coagulation syndrome. *Obstet Gynecol Reprod.* 2020;**14**(2):123-31. doi: [10.17749/2313-7347.132](https://doi.org/10.17749/2313-7347.132).
 8. Simmons J, Pittet JF. The coagulopathy of acute sepsis. *Curr Opin Anaesthesiol.* 2015;**28**(2):227-36. doi: [10.1097/ACO.000000000000163](https://doi.org/10.1097/ACO.000000000000163). [PubMed: 25590467].
 9. Carugno J, Sardo AD, Alonso L, Haimovich S, Campo R, De Angelis C, et al. COVID-19 pandemic. Impact on hysteroscopic procedures: a consensus statement from the global congress of hysteroscopy scientific committee. *J Minim Invasive Gynecol.* 2020;**27**(5):988-92. doi: [10.1016/j.jmig.2020.04.023](https://doi.org/10.1016/j.jmig.2020.04.023). [PubMed: 32339754].
 10. Sutton D, Fuchs K, D'alton M, Goffman D. Universal screening for SARS-CoV-2 in women admitted for delivery. *N Engl J Med.* 2020;**382**(22):2163-4. doi: [10.1056/NEJMc2009316](https://doi.org/10.1056/NEJMc2009316). [PubMed: 32283004].
 11. Watkins J. Preventing a covid-19 pandemic. *BMJ.* 2020; **368**:m810. doi: [10.1136/bmj.m810](https://doi.org/10.1136/bmj.m810). [PubMed: 32111649].
 12. Pryor A. SAGES and EAES recommendations regarding surgical response to covid-19 crisis. SAGES. Available at: [URL: https://www.sages.org/recommendations-surgical-response-covid-19/](https://www.sages.org/recommendations-surgical-response-covid-19/); 2020.
 13. van Kasteren PB, van der Veer B, van den Brink S, Wijsman L, de Jonge J, van den Brandt A, et al. Comparison of commercial RT-PCR diagnostic kits for COVID-19. *J Clin Virol.* 2020;**128**:104412. doi: [10.1016/j.jcv.2020.104412](https://doi.org/10.1016/j.jcv.2020.104412). [PubMed: 32416600].
 14. Fang Y, Zhang H, Xie J, Lin M, Ying L, Pang P, et al. Sensitivity of chest CT for COVID-19: comparison to RT-PCR. *Radiology.* 2020;**296**(2):E112-7. doi: [10.1148/radiol.2020200432](https://doi.org/10.1148/radiol.2020200432). [PubMed: 32073353].
 15. Mardani R, Vasmehjani AA, Zali F, Gholami A, Nasab SDM, Kaghazian H, et al. Laboratory parameters in detection of COVID-19 patients with positive RT-PCR; a diagnostic accuracy study. *Arch Acad Emerg Med.* 2020;**8**(1):e43. [PubMed: 32259132].
 16. Giannis D, Ziogas IA, Gianni P. Coagulation disorders in coronavirus infected patients: COVID-19, SARS-CoV-1, MERS-CoV and lessons from the past. *J Clin Virol.* 2020;**127**:104362. doi: [10.1016/j.jcv.2020.104362](https://doi.org/10.1016/j.jcv.2020.104362). [PubMed: 32305883].
 17. Sharifi-Razavi A, Karimi N, Rouhani N. COVID-19 and intracerebral haemorrhage: causative or coincidental? *New Microbes And New Infect.* 2020;**35**:100669. doi: [10.1016/j.nmni.2020.100669](https://doi.org/10.1016/j.nmni.2020.100669). [PubMed: 32322398].
 18. Poyiadji N, Shahin G, Noujaim D, Stone M, Patel S, Griffith B. COVID-19-associated acute hemorrhagic necrotizing encephalopathy: CT and MRI features. *Radiology.* 2020; **296**(2):E119-20. doi: [10.1148/radiol.2020201187](https://doi.org/10.1148/radiol.2020201187).
 19. Carvalho A, Alqusairi R, Adams A, Paul M, Kothari N, Peters S, et al. SARS-CoV-2 gastrointestinal infection causing hemorrhagic colitis: implications for detection and transmission of COVID-19 disease. *Am J Gastroenterol.* 2020;**115**(6):942-6. doi: [10.14309/ajg.0000000000000667](https://doi.org/10.14309/ajg.0000000000000667). [PubMed: 32496741].
 20. Shi C, Wang C, Wang H, Yang C, Cai F, Zeng F, et al. The potential of low molecular weight heparin to mitigate cytokine storm in severe covid-19 patients: a retrospective clinical study. *Clin Transl Sci.* 2020;In Press. doi: [10.1111/cts.12880](https://doi.org/10.1111/cts.12880). [PubMed: 32881340].