



# Laparoscopic Cholecystectomy in Situs Inversus, a Novel Port Placement Technique, Two Case Reports, and Review of Literature

Alireza Tavassoli<sup>1</sup>, Tooraj Zandbaf<sup>2\*</sup> and Alireza Rezapanah<sup>3</sup>

<sup>1</sup>Professor of General Surgery, Endoscopic and Minimally Invasive Surgery Research Center, Ghaem Hospital, Faculty of Medicine, Mashhad University of Medical Sciences, Mashhad, Iran

<sup>2</sup>Assistant Professor of General Surgery, Faculty of Medicine, Islamic Azad University, Mashhad Branch, Mashhad, Iran

<sup>3</sup>Assistant Professor of General Surgery, Surgical Oncology Research Center, Emam Reza Hospital, Faculty of Medicine, Mashhad University of Medical Sciences, Mashhad, Iran

\* **Corresponding author:** Tooraj Zandbaf, Faculty of Medicine, Islamic Azad University, Mashhad Branch, Mashhad, Iran. Tell: +989155114523; Email: tooraj.zandbaf@gmail.com

Received 2021 August 17; Revised 2021 August 12; Accepted 2021 May 26.

## Abstract

**Background:** Situs Inversus Totalis (SIT) is a rare and silent autosomal recessive disease in which all organs are on the opposite side. Diagnosis of gallbladder diseases will be difficult due to these anatomical changes. Laparoscopic cholecystectomy is the standard treatment for gallbladder diseases but is technically challenging for patients.

**Case presentation:** Two 52- and 64-year-old women with known SIT who complained of intermittent epigastric pain and nausea after eating fatty and bulky meals were examined. With the help of abdominal ultrasound, a gallbladder on the left side of the abdomen with multiple gallstones was shown.

**Results:** Since the successful primary cholecystectomy was performed on a patient with SIT in 1991, several modifications have been made for port insertion. Surgeons try to overcome technical problems by making various adjustments compared to conventional laparoscopic cholecystectomy.

**Conclusion:** Laparoscopic cholecystectomy in patients with SIT is safe. However, laparoscopic cholecystectomy is challenging due to anatomical changes in the SIT. Our proposed method of port placement helps right-handed surgeons for safer and easier dissection.

**Keywords:** Case report, Cholelithiasis, Cholecystitis, Situs inversus totalis, Laparoscopic cholecystectomy

## 1. Background

Situs Inversus Totalis (SIT) was represented by Fabricius in 1600 and the first laparoscopic cholecystectomy was performed on a patient with SIT in 1991 (1). SIT is a rare and silent autosomal recessive disorder that occurs in 1:5,000 to 1:20,000 people and the male: female incidence is 1:1 with no racial predilection. The gallbladder is on the left, whereas the stomach and spleen are on the right due to the atypical anatomy of “mirror image” related to SIT. Surgeons must remember this anatomy to diagnose and treat patients with SIT and gallstone disease (2,3). Management of Cholelithiasis in the patient with SIT is challenging because of an underlying anatomical variation (4,5). More than 60 cases of laparoscopic cholecystectomy are reported in patients with SIT, principally for cholelithiasis and acute cholecystitis (6). We report two female SIT patients with biliary colic who underwent laparoscopic cholecystectomy. Our work has been documented by the SCARE guidelines (7).

## 2. Case presentation

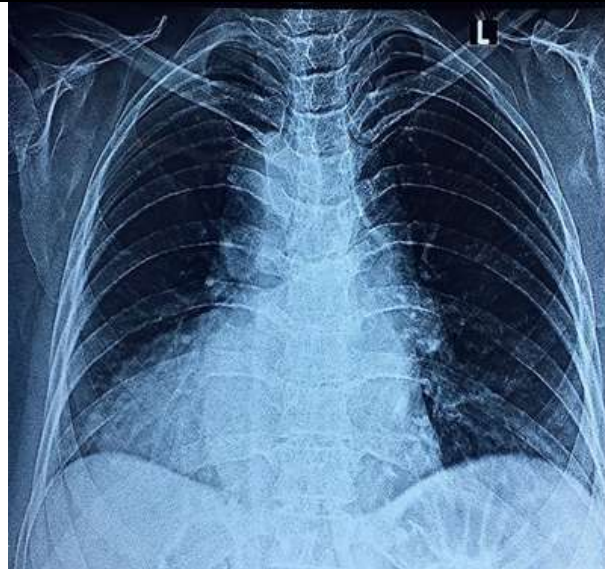
Two 52- and 64-year-old women were examined for intermittent abdominal pain and nausea after eating bulky and fatty meals one month apart. Patients were aware of the presence of SIT. These

patients had admitted to the emergency department due to abdominal pain to be treated with analgesia and antacids with symptomatic improvement. The clinical examination was unremarkable with no signs of jaundice or abdominal tenderness. Complete blood count (CBC) and also the liver and kidney function tests were normal. The presence of a gallbladder on the left side of the abdomen with a large number of small stones was reported by abdominal ultrasound. Normal bile ducts were reported. Patients were scheduled for elective laparoscopic cholecystectomy. A chest x-ray was performed for the 64-year-old patient at the hospital (Figure. 1).

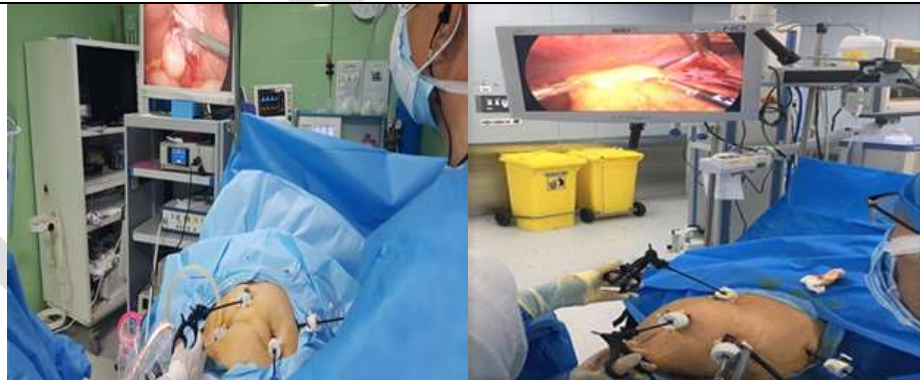Port insertion was performed after general anesthesia and P&D, while the patient was placed in the supine position. At first, a 10 mm port was placed in the umbilicus with an open technique for the camera. A 30° laparoscope was inserted after the pneumoperitoneum was established, and the presence of a left-sided gallbladder was confirmed. Secondly, a 5 mm port was placed in the right-sided subxiphoid area to hold the gallbladder by the assistant. Then a 5 mm port was placed in the left midclavicular line, 10 cm below the rib edge for the surgeon's left hand, and finally a 5 mm port in the left posterior axillary line, 2 cm below the rib edge for the surgeon's right hand. Monitor and camera assistant needs to be placed on the right side of the patient,

whereas surgeon on the left side (Figure 2). The patient was placed in the reversed Trendelenburg position and slightly to the right. The gallbladder was on the left and the stomach and spleen were on the right (Figure 3). The right-handed surgeon grasped Hartmann's pouch through the left midclavicular port with his left hand and pulled it to the medial, and dissected the adhesion with his right hand through the posterior axillary port. Dissection was performed with more difficulty due to unfamiliarity with this type of abnormal anatomy. The cystic duct and artery

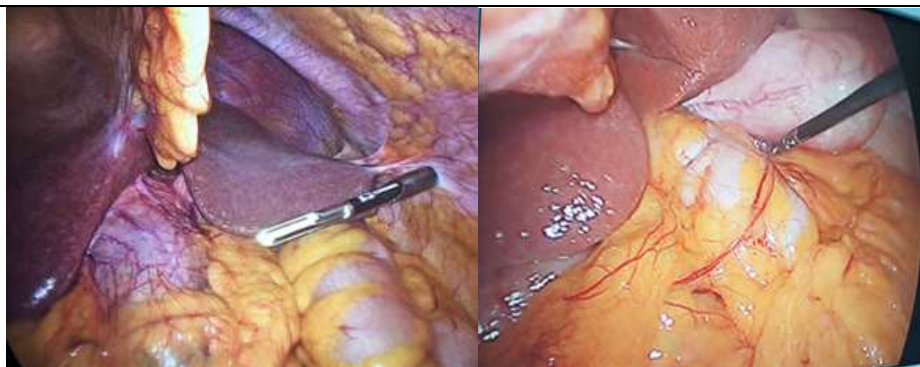
were doubly clipped separately and divided after accurate dissection of the Calot triangle and critical of safety view achievement. The gallbladder was normally removed from its bed by electrocautery and, under direct vision, extracted in a retrieval bag via the camera port. The first operation (52-year-old woman) lasted 75 minutes and the second operation (64-year-old woman) lasted 30 minutes using the same method. On postoperative day 1, patients had an uneventful postoperative period and were discharged.



**Figure 1.** The cardiac shadow in the right side of the chest and the gastric bubble under the right dome of the diaphragm could be seen on a chest X-ray.



**Figure 2.** The Operating room equipment and port placement.



**Figure 3.** Gallbladder placement on the left side of the abdomen.

### 3. Discussion

Acute cholecystitis is difficult to diagnose in patients with previously unknown SIT. Most cases present with left upper quadrant pain. Epigastric pain has been reported in one-third of patients (6). Since the successful primary cholecystectomy was performed in a patient with SIT in 1991, 85 cases have been reported in the literature (8). One of the foremost necessary steps is to place the trocars to get a critical view of safety and reduce the risks of bile duct injuries. The fact that a number of the critical dissection should be conjointly performed by the left hand, poses a technical issue for right-handed surgeons (6).

Laparoscopic cholecystectomy is a gold standard treatment for acute cholecystitis which should be varied to accommodate the patient's anatomy in patients with SIT. There were two kinds of laparoscopy trocar placements: the "American Mirror Technique" and also the "French Mirror Technique". As for the "American Mirror Technique", the patient is placed in the supine position, with the right arm or each arm in abduction. The surgeon stands on the right aspect of the patient. A 10mm trocar is inserted below the umbilicus for the scope. Once CO<sub>2</sub> insufflation is up to 12–14mmHg, three other ports are inserted within the epigastrium, left subcostal region on the midclavicular line, and left the subcostal region on the anterior axillary line. Concerning the "French Mirror Technique", the patient is placed in the supine position, and the right arm or both arms in the abduction. The surgeon stands between the patient's legs or on the right side. A 10mm trocar is inserted below the umbilicus for the optic. Once CO<sub>2</sub> insufflation is up to 12–14mmHg, a second trocar is inserted within the epigastrium, followed by two alternative trocars to the left flank and right subcostal port. This procedure was easier for left-handed surgeons. "American Mirror Technique" appears to be a quicker technique for right-handed surgeons. Dissection can be performed using the epigastric trocar just in case of the "American Mirror Technique" and therefore the right subcostal trocar in case of the "French Mirror Technique". This procedure is more difficult due to the anatomy of mirror image, particularly for right-handed surgeons (9–11).

An intraoperative cholangiogram may be performed if there is some uncertainty regarding the ductal anatomy. The utilization of an extra port or a change of the typical entry site can also be considered. As vascular and biliary anomalies are common in patients with SIT, intraoperative cholangiogram or preoperative magnetic resonance imaging is facilitative during surgery (12).

Fluorescence cholangiography could be an innovation within the field of navigation surgery that is safe and straightforward. It will be employed in

real-time to spot extrahepatic biliary structures throughout the surgery. This technique involves the administration of indocyanine green (ICG) by intravenous injection 30 min before surgery. ICG is taken up by the liver and entirely excreted in the bile, helping the surgeon to differentiate between components of the biliary system (13).

To date, to the best of our knowledge, no standard technique has been introduced for port insertion in patients with SIT during Laparoscopic cholecystectomy. In our operation, the surgeon was positioned on the left side of the patient while the surgical equipment and camera assistant were on the right side. The distinguishing feature of our proposed port insertion method is that the dissection is performed by a right-handed surgeon. The left posterior axillary port was assigned as the dissecting port, as it is more convenient to work with the surgeon's right hand. As a result, the surgeon can perform safer, easier and quicker dissections using the dominant hand.

### 6. Conclusion

Laparoscopic cholecystectomy is safe in patients with SIT patients. However, diagnosis and surgical management of gallbladder diseases are challenging. This type of surgery is especially difficult for right-handed surgeons. Surgeons try to overcome technical problems by making various modifications compared to conventional laparoscopic cholecystectomy. Our proposed method of port placement would be a great help to right-handed surgeons for laparoscopic cholecystectomy in patients with SIT.

### Conflict of Interest

The authors declare that there is no conflict of interest regarding the publication of the present study.

### Consent

Patients' informed written consent was obtained for the publication of these case reports and accompanying photographs.

### Funding

This case report had no funding or sponsorship.

### Acknowledgments

The authors would like to express their sincere gratitude to Razavi Hospital and Mehr Hospital of Mashhad, where these two surgeries were conducted.

### Author contribution

AT performed the surgery and reviewed the manuscript, TZ wrote the manuscript and reviewed the literature. AR reviewed the literature. All authors read and approved the final manuscript.

## References

1. Campos L, Sipes E. Laparoscopic cholecystectomy in a 39-year-old female with situs inversus. *J Laparoendosc Surg.* 1991;**1**(2):123-5. doi: [10.1089/lps.1991.1.123](https://doi.org/10.1089/lps.1991.1.123). [PubMed: [1834260](https://pubmed.ncbi.nlm.nih.gov/1834260/)].
2. Tsoucalas G, Thomaidis V, Fiska A. Situs inversus totalis: always recall the uncommon. *Clin Case Rep.* 2019;**7**(12):2575-6. doi: [10.1002/ccr3.2433](https://doi.org/10.1002/ccr3.2433). [PubMed: [31893103](https://pubmed.ncbi.nlm.nih.gov/31893103/)].
3. Phothong N, Akaraviputh T, Chinswangwatanakul V, Trakarnsanga A. Simplified technique of laparoscopic cholecystectomy in a patient with situs inversus: a case report and review of techniques. *BMC Surg.* 2015;**15**(1):23. doi: [10.1186/s12893-015-0012-6](https://doi.org/10.1186/s12893-015-0012-6). [PubMed: [25880817](https://pubmed.ncbi.nlm.nih.gov/25880817/)].
4. Malik FS, Butt UI, Khan WH, Bilal SM, Umar M. Laparoscopic cholecystectomy in situs inversus totalis. *J Coll Physicians Surg Pak.* 2019;**29**(10):1000-2. doi: [10.29271/jcpsp.2019.10.1000](https://doi.org/10.29271/jcpsp.2019.10.1000). [PubMed: [31564278](https://pubmed.ncbi.nlm.nih.gov/31564278/)].
5. Demiryilmaz I, Yilmaz I, Albayrak Y, Peker K, Sahin A, Sekban N. Laparoscopic cholecystectomy in patients with situs inversus totalis: literature review of two patients. *Iran Red Crescent Med J.* 2012;**14**(12):826-8. doi: [10.5812/ircmj.4806](https://doi.org/10.5812/ircmj.4806). [PubMed: [23482252](https://pubmed.ncbi.nlm.nih.gov/23482252/)].
6. Du T, Hawasli A, Summe K, Meguid AA, Lai C, Sadoun M. Laparoscopic cholecystectomy in a patient with situs inversus totalis: Port placement and dissection techniques. *Am J Case Rep.* 2020;**21**:e924896. doi: [10.12659/AJCR.924896](https://doi.org/10.12659/AJCR.924896). [PubMed: [32886654](https://pubmed.ncbi.nlm.nih.gov/32886654/)].
7. Agha RA, Borrelli MR, Farwana R, Koshy K, Fowler AJ, Orgill DP, et al. The SCARE 2018 statement: updating consensus Surgical CAse REport (SCARE) guidelines. *Int J Surg.* 2018;**60**:132-6. doi: [10.1016/j.ijisu.2018.10.028](https://doi.org/10.1016/j.ijisu.2018.10.028). [PubMed: [30342279](https://pubmed.ncbi.nlm.nih.gov/30342279/)].
8. Alkhlaiwy O, Almuhsin AM, Zakarneh E, Taha MY. Laparoscopic cholecystectomy in situs inversus totalis: case report with review of techniques. *Int J Surg Case Rep.* 2019;**59**:208-12. doi: [10.1016/j.ijscr.2019.05.050](https://doi.org/10.1016/j.ijscr.2019.05.050). [PubMed: [31181389](https://pubmed.ncbi.nlm.nih.gov/31181389/)].
9. Chaouch MA, Jerraya H, Dougaz MW, Nouria R, Dziri C. A systematic review of laparoscopic cholecystectomy in situs inversus. *J Investig Surg.* 2019;**34**(3):324-33. doi: [10.1080/08941939.2019.1622822](https://doi.org/10.1080/08941939.2019.1622822). [PubMed: [31164015](https://pubmed.ncbi.nlm.nih.gov/31164015/)].
10. Mohammed AA, Arif SH. Laparoscopic cholecystectomy for left-sided gall bladder in situs inversus totalis patient, a technically demanding procedure. *Ann Med Surg.* 2019;**47**:1-4. doi: [10.1016/j.amsu.2019.09.002](https://doi.org/10.1016/j.amsu.2019.09.002). [PubMed: [31645939](https://pubmed.ncbi.nlm.nih.gov/31645939/)].
11. Zatir S, Medjamea A, Bouazzaoui A, Lounici S, Bouchakor S, Kroumli B, et al. Laparoscopic cholecystectomy on complete situs inversus : about a case, how does it work? *Surg Clin J.* 2020;**2**:28-9.
12. Moyon C MA, Rojas CL, Moyon C FX, Aguayo WG, Molina GA, Ochoa C, et al. Acute cholecystitis and residual choledocholithiasis in a situs inversus patient, successful laparoscopic approach and ERCP a case report from Ecuador. *Ann Med Surg.* 2020;**54**:101-5. doi: [10.1016/j.amsu.2020.04.012](https://doi.org/10.1016/j.amsu.2020.04.012). [PubMed: [32426127](https://pubmed.ncbi.nlm.nih.gov/32426127/)].
13. Rungsakulkij N, Tangtawee P. Fluorescence cholangiography during laparoscopic cholecystectomy in a patient with situs inversus totalis: a case report and literature review. *BMC Surg.* 2017;**17**(1):43. doi: [10.1186/s12893-017-0242-x](https://doi.org/10.1186/s12893-017-0242-x). [PubMed: [28427402](https://pubmed.ncbi.nlm.nih.gov/28427402/)].