



A woman with *Clostridium tetani* infection and metastatic breast cancer: A case report

Aria Kasiri^{1*}, Mahdi Baladieh², Shiva Shabani³ and Majid Akbari⁴

¹Bachelor of Laboratory Science, School of Medicine, Arak University of Medical Sciences, Arak, Iran

²Medical student, School of Medicine, Arak University of Medical Sciences, Arak, Iran

³Department of Infectious Diseases, School of Medicine, Arak University of Medical Sciences, Arak, Iran

⁴Infectious Research Center, Arak University of Medical Sciences, Arak, Iran

* **Corresponding author:** Aria Kasiri, Bachelor of Laboratory Science, School of Medicine, Arak University of Medical Sciences, Arak, Iran. Email: Aria.kasiri78@gmail.com

Received 17 August 2023; Revised 30 September 2023; Accepted 08 November 2023.

Abstract

Tetanus could be a genuine and possibly dangerous neurological infection caused by the tetanus poison delivered by the bacterium *Clostridium tetani*. Infection occurs through contaminated wounds, burns, surgical wounds, and insect bites. Related symptoms include muscle spasms, autonomic instability, and respiratory failure. Complications occur in the form of fractures, sprains, muscle tears, and death. Early diagnosis and prompt treatment are crucial to prevent complications and improve outcomes. Risk factors for tetanus infection include the lack of routine vaccinations, wound contamination with *C. tetani*-contaminated soil, and improper hygiene practices during childbirth. We presented a case report of a 32-year-old woman with a history of breast cancer, who developed a rapidly growing and foul-smelling mass. Despite early diagnosis and treatment measures, the patient did not respond to treatment and died due to the severity of mixed infections. The case highlights the importance of early diagnosis, prompt treatment, and routine vaccinations to prevent complications and improve outcomes in tetanus infection.

Keywords: Breast cancer, *Clostridium*, *Clostridium tetani*, Tetanus, Tetanus toxin

1. Background

Tetanus is an infectious neurological disease characterized by convulsive paralysis. The cause of tetanus is the tetanus toxin produced by the bacterium *Clostridium tetani*. This bacterium is commonly found in soil and infects wounds (1). One of the most potent toxins available, tetanus toxin, causes spasticity by blocking the release of inhibitory neurotransmitters in the central nervous system (2). The symptoms of tetanus include trismus, risus sardonicus (3), widespread muscle spasms in response to stimuli, such as sound or touch (3, 4), and autonomic instability (3). The risk factors associated with tetanus infection involve wound contamination with *Clostridium tetani* contaminated soil (3), improper hygiene practices during childbirth (5), especially in areas with poor immunization and limited access to clean childbirth and umbilical cord care (6), the lack of routine tetanus, diphtheria, and whooping cough vaccinations (5-8), age (5), and environmental factors, such as social, economic, environmental, and biological factors (6). Complications occurring due to infection with tetanus include respiratory failure from muscle spasms of the chest and diaphragm (9), injuries from muscle spasms, such as fractures, sprains, and muscle tears (3), and death. Mortality from this disease in people not receiving appropriate medical care has been reported to be as high as 46.5% (3).

The diagnosis of tetanus is often based on the person's clinical findings (10). The diagnosis is made in the laboratory by a bacterial culture from the wound or the patient's blood (10) and by genetic bacterial sequencing (11). Treatment for *C. tetani* involves antitoxins, muscle relaxants, antibiotics, tranquilizers, combination drugs (12), and using IgY (13). The present article reports the case of a 32-year-old woman with metastatic breast cancer infected with *C. tetani* during her hospitalization in the intensive care unit (ICU).

2. Results

The patient was a 32-year-old woman with a weight of 65 kg, a body mass index of 23, and a history of breast cancer. The patient had undergone mastectomy twice in Afghanistan and Pakistan; nonetheless, she was still suffering from breast cancer metastasizing to the skin and bleeding from the cancer site. The cancerous mass in her breast created an infectious mass with rapid growth and a very unpleasant smell. The patient was referred to the hospital with complaints of fever, chills, pain, constipation, weak pulse, and right upper-side edema. The patient's level of consciousness was appropriate, and she was aware of time, place, person, and questions. After taking samples from the patient's infectious mass, *C. tetani* bacillus containing spores was detected in her direct smear. In the patient's smear, in addition to *C. tetani*, there were a variety of Gram-

positive and Gram-negative bacteria. According to the patient's statements, she had no history of tetanus vaccination. In order to confirm the presence of *C. tetani*, the samples were taken from slightly deeper parts of the lesion and cultured in a Thioglycollate broth medium. After growth, a smear was prepared from the deep part of the culture medium, and the presence of *C. tetani* bacteria was confirmed once more. Since the patient presented with septic shock and was admitted to the ICU in previous hospitals, her local epidemiology included infections resistant to treatment with meropenem, colistin, and linezolid. Moreover, during hospitalization, the patient received seven units of Pace-Cell, and the attending physician prescribed an immediate injection of Diazepam 5 mg in case of spasms.

Clostridium tetani infection was diagnosed in the laboratory in the early stages of infection. Since this patient was hospitalized for a long time, it seems that the infection with *C. tetani* was a hospital infection.

The patient died 14 days after admission and four days after the diagnosis of *C. tetani* at the injection site due to septic shock and necrotizing fasciitis. During the hospitalization, the microbiology laboratory detected a variety of bacteria, including *Klebsiella*, *Proteus*, and *Acinetobacter*, in addition to *C. tetani* from the patient's lesion. In addition, one day before the patient's death, numerous fly larvae were observed in the wound and were cleaned. During this patient's hospitalization, none of the symptoms of *C. tetani*, such as muscle spasms, were observed.

3. Discussion

Clostridium tetani is an infection with a high lethal potential. This bacterium can enter the body through wounds, burns, surgical wounds, and insect bites (14, 15). Early diagnosis and prompt treatment of tetanus are crucial for preventing complications and improving outcomes (16).

Previous studies have demonstrated that *C. tetani* bacteria have been isolated from the equipment of cribs and other inanimate objects and environmental surfaces in the hospital. The risk factors for the transmission of this hospital infection to patients include open wounds, long-term hospitalization (17-20), and the lack of vaccination and personal protection facilities (19, 20).

In our case, the presence of *C. tetani* occurred very quickly and on time, which made us alert to the occurrence of tetanus toxin symptoms. What worried us was the lack of a history of tetanus vaccination in this patient.

In the case of Jin Wang, who had skin cancer and a scar on her right hip, as in the case mentioned by us, she had a history of removing the cancerous mass; nonetheless, there was no recovery. This person suffered from repeated seizures, trismus, and opisthotonus due to infection of the lesion site with *C. tetani*. This was different from our case, which was probably due to the large size of the patient's mass, the lack of access of bacteria to peripheral nerves, and the ability to inject toxins into the blood. Even considering the lack of vaccination in our case, this possibility was high; however, it did not occur (21).

Kazuhiro Nomura, who experienced a relapse of left breast cancer following treatment, also contracted a *C. tetani* infection and exhibited various symptoms, such as trismus and cervical curvature disruption. Furthermore, the stiffness in her muscles was alleviated (22).

The main difference between this case and the two cases mentioned above was the recovery in the former. Nonetheless, in our case, the disease led to death, probably due to the conditions of the patient when she was admitted to the hospital. Since she had a history of two failed breast cancer operations in Afghanistan and Pakistan, and despite early diagnosis and treatment measures, the patient did not respond to treatment and died due to the severity of other various bacterial infections.

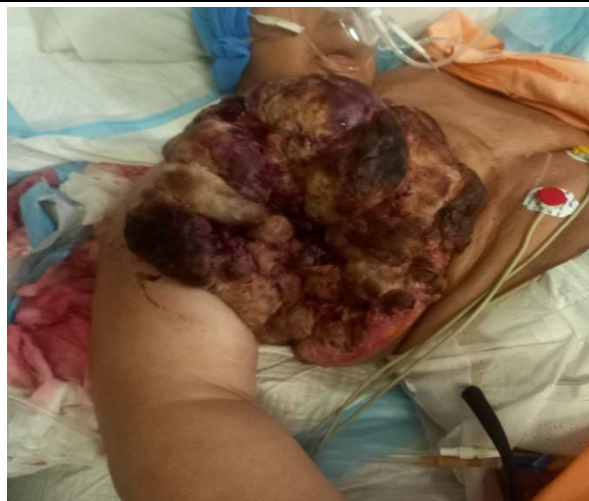

Figure 1. A patient with a cancerous lesion in the right breast

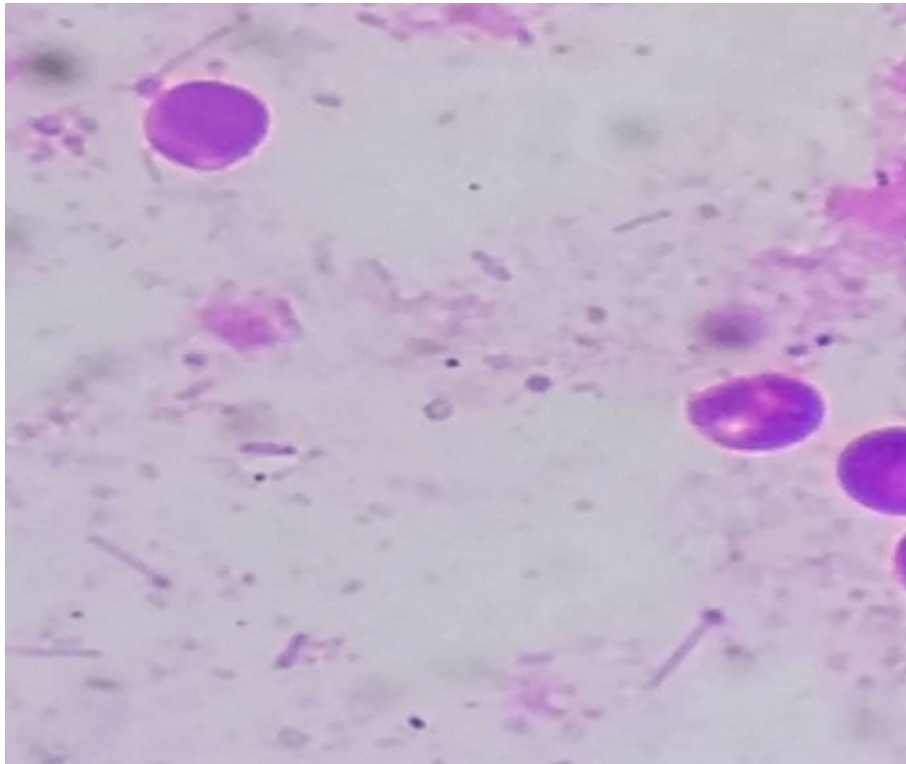


Figure 2. Direct slide from the lesion site, observation of club-shaped bacilli of *Clostridium tetani* containing round spores at its tip

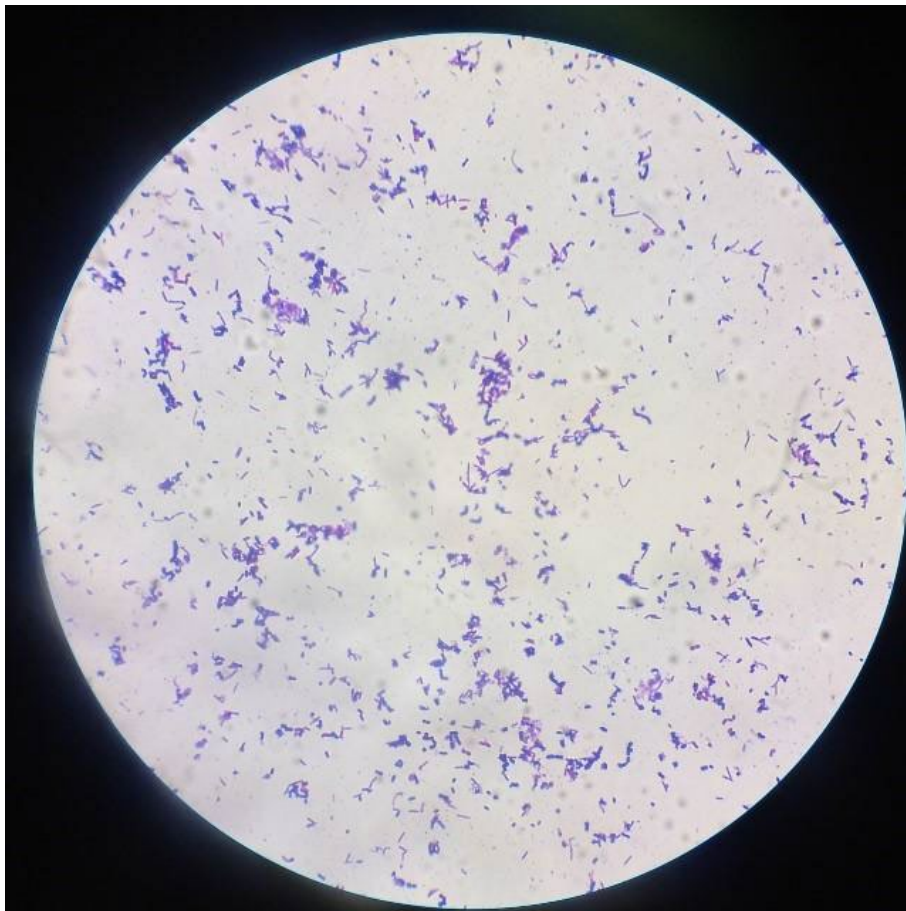


Figure 3. Smear stained with warm dye from the depth of thioglycorate culture medium, observation of elongated bacilli without *Clostridium tetani* spores

4. Conclusion

It is crucial to be vigilant about *C. tetani* infection in patients admitted to the ICU, particularly those with open ulcers and individuals who have not been vaccinated against tetanus. Early diagnosis of this infection in susceptible patients can prevent fatal complications. This article highlights the importance of recognizing the high potential for *C. tetani* infection in ICU patients.

Acknowledgments

No acknowledgments.

Footnotes

Conflicts of Interest: No conflict of interest.

Author Contribution: aria kasiri 70%. Mahdi Baladieh 40%.

Funding: No funding.

Ethical Statements: The patient and her primary caregiver provided a consent letter in their native language for the publication of this case report.

References

- Popoff MR. Tetanus in animals. *J Vet Diagn Invest.* 2020;**32**(2):184-91. doi: [10.1177/1040638720906814](https://doi.org/10.1177/1040638720906814). [PubMed: [32070229](https://pubmed.ncbi.nlm.nih.gov/32070229/)].
- Dong M, Masuyer G, Stenmark P. Botulinum and Tetanus Neurotoxins. *Annu Rev Biochem.* 2019;**88**:811-37. doi: [10.1146/annurev-biochem-013118-111654](https://doi.org/10.1146/annurev-biochem-013118-111654). [PubMed: [30388027](https://pubmed.ncbi.nlm.nih.gov/30388027/)].
- Dittrich KC, Keilany B. Tetanus: lest we forget. *CJEM.* 2001;**3**(1):47-50. doi: [10.1017/s1481803500005170](https://doi.org/10.1017/s1481803500005170). [PubMed: [17612443](https://pubmed.ncbi.nlm.nih.gov/17612443/)].
- Miller SW. Adverse Medication Events: Tetanus Toxoid Reaction: Too Much of a Good Thing. *Journal of Pharmacy Practice.* 1997;**10**(6):365-66. doi: [10.1177/089719009701000601](https://doi.org/10.1177/089719009701000601).
- Belay AT, Fenta SM, Agegn SB, Muluneh MW. Prevalence and risk factors associated with rural women's protected against tetanus in East Africa: Evidence from demographic and health surveys of ten East African countries. *PLoS One.* 2022;**17**(3):e0265906. doi: [10.1371/journal.pone.0265906](https://doi.org/10.1371/journal.pone.0265906). [PubMed: [35324988](https://pubmed.ncbi.nlm.nih.gov/35324988/)].
- Rey M, Guillaumont P, d'Intignano BM. Benefits of immunization versus risk factors in tetanus. *Dev Biol Stand.* 1979;**43**:15-23. [PubMed: [520667](https://pubmed.ncbi.nlm.nih.gov/520667/)].
- Gowa M, Zakai F, Shahzad M, Ahmed H, Ashfaq M, Khoso Z. Risk factors and clinical Outcome of Tetanus in Pediatric ICU of a developing country. *The Professional Medical Journal.* 2022;**29**(6):844-8. doi: [10.29309/TPMJ/2022.29.06.6662](https://doi.org/10.29309/TPMJ/2022.29.06.6662).
- Orimadegun AE, Orimadegun BE, Adepoju AA. Immunity Against Tetanus Infection, Risk Factors for Non-Protection, and Validation of a Rapid Immunotest Kit among Hospitalized Children in Nigeria. *Front Neurol.* 2013;**24**:4:142. doi: [10.3389/fneur.2013.00142](https://doi.org/10.3389/fneur.2013.00142). [PubMed: [24069018](https://pubmed.ncbi.nlm.nih.gov/24069018/)].
- Almas T, Niaz M A, Zaidi SM, Haroon M, et al. The Spectrum of Clinical Characteristics and Complications of Tetanus: A Retrospective Cross-Sectional Study From a Developing Nation. *Cureus.* 2021;**13**(6):e15484. doi: [10.7759/cureus.15484](https://doi.org/10.7759/cureus.15484). [PubMed: [34268020](https://pubmed.ncbi.nlm.nih.gov/34268020/)].
- Smietańska K, Rokosz-Chudziak N, Rastawicki W. Charakterystyka Clostridium tetani i laboratoryjna diagnostyka tezca Characteristics of Clostridium tetani and laboratory diagnosis of tetanus. *Med Dosw Mikrobiol.* 2013;**65**(4):285-95. [PubMed: [24730217](https://pubmed.ncbi.nlm.nih.gov/24730217/)].
- An Y, Guo Y, An Z, Peng Y, Fan M, Li Z, et al. Diagnosis of Tetanus Assisted by Next-Generation Sequencing Analysis of Etiology: A Case Report. *Ann Clin Case Rep.* 2021;**6**: 2023.
- Nakae H, Yasuhito I, Satoh K, Kitamura T, Kameyama K, Nara T, et al. Treatment for tetanus applying Kampo medicine: Administration of shakuyakukanzoto. *Traditional & Kampo Medicine.* 2021;**8**. doi: [10.1002/tkm2.1283](https://doi.org/10.1002/tkm2.1283).
- Meshad E, Galila E, Selim A, Hamouda F. A New Trend in Donkeys Tetanus Treatment Using IgY. *Researcher.* 2013;**5**:23-9.
- Laverse E, Dhamija K, Meyers M, Grant K. Pre-emptive treatment for Clostridium tetani: importance of early recognition and treatment in the community. *BMJ Case Rep.* 2009;2009:bcr03.2009.1649. doi: [10.1136/bcr.03.2009.1649](https://doi.org/10.1136/bcr.03.2009.1649). [PubMed: [21686979](https://pubmed.ncbi.nlm.nih.gov/21686979/)].
- Hassel B. Tetanus: pathophysiology, treatment, and the possibility of using botulinum toxin against tetanus-induced rigidity and spasms. *Toxins (Basel).* 2013;**5**(1):73-83. doi: [10.3390/toxins5010073](https://doi.org/10.3390/toxins5010073). [PubMed: [23299659](https://pubmed.ncbi.nlm.nih.gov/23299659/)].
- Hamdi R, Afellah M, Ridal M, Elalami MA. Cephalic Tetanus Presenting as Peripheral Facial Palsy: A Case Report. *Cureus.* 2023;**15**(4):e37116. doi: [10.7759/cureus.37116](https://doi.org/10.7759/cureus.37116). [PubMed: [37153324](https://pubmed.ncbi.nlm.nih.gov/37153324/)].
- Chandrashekar MR, Rathish KC, Nagesha CN. Reservoirs of nosocomial pathogens in neonatal intensive care unit. *J Indian Med Assoc.* 1997;**95**(3):72-7. [PubMed: [9212573](https://pubmed.ncbi.nlm.nih.gov/9212573/)].
- Cross WW 3rd, Swiontkowski MF. Treatment principles in the management of open fractures. *Indian J Orthop.* 2008;**42**(4):377-86. doi: [10.4103/0019-5413.43373](https://doi.org/10.4103/0019-5413.43373). [PubMed: [19753224](https://pubmed.ncbi.nlm.nih.gov/19753224/)].
- Zheng L, Wang X, Zhou C, Liu Q, Li S, et al. Analysis of the Infection Status of Healthcare Workers in Wuhan During the COVID-19 Outbreak: A Cross-sectional Study. *Clin Infect Dis.* 2020;**71**(16):2109-13. doi: [10.1093/cid/ciaa588](https://doi.org/10.1093/cid/ciaa588). [PubMed: [32409825](https://pubmed.ncbi.nlm.nih.gov/32409825/)].
- Piscitelli A, Cacciatore S, Ambrosio F, Ragozzino R, Pasquini FM, Incordino F, D'Angelo E, Gerardino L, Maggi, L, Landi, F. Clostridium tetani Infection in a Geriatric Patient: Do Not Let Your Guard Off! *Ann Geriatr Med Res.* 2023;**27**(3):269-73. doi: [10.4235/agmr.23.0067](https://doi.org/10.4235/agmr.23.0067). [PubMed: [37482408](https://pubmed.ncbi.nlm.nih.gov/37482408/)].
- Wang J, Yang Y, Yang C, Lv W, Xu S, et al. Severe tetanus following ulcerated skin cancer: Case report. *Medicine (Baltimore).* 2020;**99**(31):e21529. doi: [10.1097/MD.00000000021529](https://doi.org/10.1097/MD.00000000021529). [PubMed: [32756200](https://pubmed.ncbi.nlm.nih.gov/32756200/)].
- Nomura K, Sakawaki E, Sakawaki S, Yamaoka A, Aisaka W, Okamoto H, Takeyama Y, et al. Non-surgical treatment of tetanus infection associated with breast cancer skin ulcer: a case report and literature review. *BMC Infectious Diseases.* 2021;**21**(1):1-6. doi: [10.1186/s12879-020-05739-4](https://doi.org/10.1186/s12879-020-05739-4).