



Gauze Aortic Compression and Super Massive Blood Transfusion Protocol for Injury to the Abdominal Aorta: A Case Report

Wei Huang¹, Zhao-Jin Yang², Yang Zhou³, Bin He¹, Yi-Yuan Wu⁴ and Yun-Han Jiang^{5,*}

¹Department of Anesthesiology, The People's Hospital of Leshan, Leshan, Sichuan Province, China

²Department of General Surgery, The People's Hospital of Jingyan County, Leshan, Sichuan Province, China

³Department of Cardiothoracic Surgery, The People's Hospital of Leshan, Leshan, Sichuan Province, China

⁴Department of Critical Care Medicine, The People's Hospital of Leshan, Leshan, Sichuan Province, China

⁵Department of Cardiovascular Surgery, Xinqiao Hospital, Third Military Medical University, Chongqing, Chongqing, China

*Corresponding author: Department of Cardiovascular Surgery, Xinqiao Hospital, Third Military Medical University, No. 183, Xinqiao St., Shapingba District, Chongqing, China. Tel/Fax: +86-0236877117, jiangyunhan89@163.com

Received 2017 December 09; Revised 2018 April 15; Accepted 2018 July 22.

Abstract

Introduction: Abdominal aorta injury is a rare yet lethal condition, particularly in patients at first-line hospitals, which usually lack in experience with the treatment of major vascular injuries. In this setting, the patient should initially be treated with the intent to prolong survival and enable the consultation of a physician at a tertiary hospital.

Case Presentation: This report describes a case, in whom massive blood transfusion and aortic compression with gauze were combined to maintain hemodynamics for approximately one hour successfully. The case was a 40-year-old patient with a penetrating abdominal aorta injury. This patient was admitted to the People's Hospital of Jingyan County in Leshan, People Republic of China, during May 2017. During the resuscitation process, this patient experienced a blood loss of 12 000 mL (equivalent to 2.5 folds that of a male with a 60-kg body weight) and received an approximate total volume of 9000 mL of transfused blood and blood products.

Conclusions: Although supermassive hemorrhages and transfusions approximated to 2.5 times and 2 times, respectively, blood volume of a 60-kg man are extremely rare. This study demonstrates that the simple intervention combined with a massive transfusion with gauze-based aortic compression can effectively prolong the time window, during which an abdominal aorta repair is possible. Therefore, massive transfusion and gauze-based compression are one of the most effective rescue measures to life-threatening hemorrhages.

Keywords: Aorta, Abdominal, Blood Transfusion, Hemostatic Techniques, Surgical Sponges

1. Introduction

Abdominal aorta injury is among the most lethal types of injury, with mortality rates ranging from 31% to 87% (1), particularly penetrating abdominal aortic trauma. Deep large vessels-penetrating injuries can be damaged by improvised explosive devices, gunshots, and vehicle collisions, and lethal exsanguination can occur within minutes. In this setting, emergency conventional open surgery or endovascular intervention (2) is often necessary to repair the injury. However, no matter how the vascular system is repaired, it requires an experienced surgeon, who are unavailable in first-line hospitals. Therefore, direct pressure is the intuitive choice to prolong the time window until consultation with a more experienced physician for abdominal aorta repair.

Modern resuscitative techniques, including hypotensive resuscitation, and Massive Transfusion Protocols

(MTP) involving low ratios of Packed Red Blood Cells (PRBC) to Fresh Frozen Plasma (FFP) have significantly reduced mortality associated with abdominal aorta injuries (3-9). The most commonly used definition of MTP in the trauma literature is > 10 units of pRBCs in 24 hours, which involves "damage control resuscitation" practices of the critically ill, hemorrhaging trauma patient (10). However, first-line hospitals lack experience in the resuscitation of patients with major vascular injuries and trauma, and patients, who refer to these hospitals with penetrating abdominal injuries often require consultation with a physician at a higher-level hospital. These patients must be kept alive by the maintenance of hemodynamics until the consulting physician can arrive. Accordingly, a simple and suitable technique for maintaining hemodynamics for as long as possible is needed.

Massive Transfusion Protocols, which mainly comprise of early Massive Transfusion (MT) and various ratios of

transfused blood products to whole blood, have benefitted resuscitative efforts and limited the adverse effects of aggressive crystalloid administration (9, 11, 12), and reduced mortality due to exsanguination (9, 11). In such settings, various types of hemostatic gauzes composed of specific materials, including chitosan (13), thrombin, and tranexamic acid (14), are packed into wounds and compressed for several minutes to maintain hemostasis. However, first-line hospitals are not likely to stock large amounts of hemostatic gauze, and massively hemorrhaging wounds, particularly those of the deep viscus may therefore be compressed only with common gauze.

This report describes a case of a 40-year-old male, who received an MT with a volume of approximately 9000 mL (including PRBC and FFP) and Gauze-based Aortic Compression (GAC), which allowed hemodynamic maintenance for approximately one hour until a consultation regarding abdominal aortic repair could be made with a surgeon from a tertiary hospital.

2. Case Presentation

The case was a 40-year-old male presented with a 4-cm stab wound in the upper left abdomen, from which the small intestine was protruding. He was admitted to the emergency room at the People's Hospital of Jingyan County, Leshan, People Republic of China, in May 2017. The patient had no history of other diseases and presented nausea, dizziness, palpitations, and dyspnea, pale skin and conjunctiva, abdominal tenderness, high muscle tension, and rebound pain related to the bleeding. The patient's vital signs were stable at the time of admission. An emergent abdominal computed tomography (CT) scan revealed an incision shadow in the upper left abdomen; an outward bulge corresponding to the intestine and peritoneum; subcutaneous, perihepatic, and perienteric pneumatosis, resulting from a perforation of the hollow viscera caused by the injury, a slightly higher density mass shadow indicating a potential hematoma between the stomach and pancreas, and perihepatic effusion (Figure 1). The patient was transferred immediately to an operating room for exploratory laparotomy.

During the operation, the protruding section of the small intestine was cleaned and returned to the abdominal cavity. After the further opening of the abdominal cavity via an extension of 20 cm from the wound, the first-line surgeons observed an approximate blood volume of 2000 mL and a clot of approximately 500 g in the abdominal cavity; jejunal perforations with lengths of approximately 1.0 and 1.5 cm and approximately 70 cm and 90 cm, respectively, from the flexor ligament, with progressive bleeding; a penetrating injury of approximately 2.5 cm in length in the left

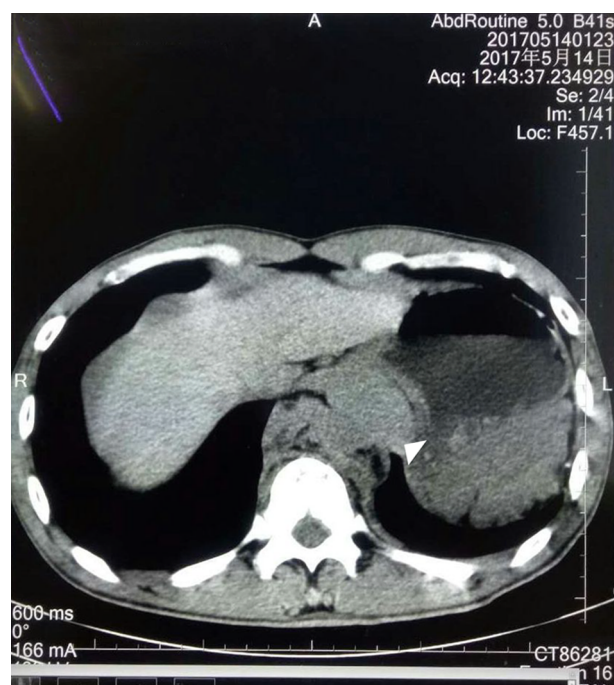


Figure 1. Computed angiography showing a rupture of abdominal aorta artery (white arrowhead)

liver and approximately 2 cm near the leading edge, with progressive bleeding; a hepatic fissure with an approximate length and depth of 2 cm and 1.5 cm, respectively, roughly 1.5 cm from the trailing edge, with progressive bleeding; and an approximately 2-cm breach of the hepatogastric ligament with pulsatile bleeding that had penetrated the retroperitoneum, where the breach was about 1.5 cm length with pulsatile bleeding. Penetrating liver injury, hepatic fissure, and jejunal perforation were repaired in a stepwise manner. A huge hematoma was observed in the retroperitoneum, once the gastrocolic ligament was incised and the stomach turned upwards. The first-line surgeons incised the retroperitoneum to free the bleeding, which had originated from a rupture of the abdominal aorta.

As the first-line surgeons lacked experience in the treatment of major vascular injuries, they informed the patient's families of the severe abdominal aorta injury and suggested a consultation with a cardiothoracic surgeon at a tertiary hospital. The families consented to this suggestion, and the surgeon at the tertiary hospital was informed of the consultation. While waiting for the consultation, they compressed the wound with gauze to maintain hemostasis and administered an MT that included 7100 mL of PRBC and 1700 mL of FFP, despite a total blood loss of

12000 mL. This super MT and GAC allowed the maintenance of a systolic blood pressure of between 60 and 100 mmHg and a heart rate of between 130 and 150 bpm (Table 1).

The surgeon from the tertiary hospital identified a 1.5-cm-long oblique rupture in the anterior wall of the abdominal aorta and sutured this lesion using a 3-0 suture with a bovine pericardium gasket. The patient was administered vasoconstrictors, including dopamine and noradrenaline, during this process, and his systolic blood pressure remained between 90 and 120 mmHg with a heart rate of 90 to 110 bpm. As no other active bleeding sites were identified, the abdominal cavity was closed. The patient's postoperative course was guided by an Intensive Care Unit (ICU) physician at the tertiary hospital, and he recovered well and was discharged after 30 days.

3. Discussion

As noted earlier, first-line hospitals tend to lack experience regarding the rescue of major vascular injuries that are accompanied by life-threatening hemorrhages. However, the patient will need to be sustained during the period between 30 minutes and 3 hours and is required to obtain a consultation with a physician from a tertiary hospital. Accordingly, immediate treatment is needed to maintain the patient's hemodynamics and to control hemorrhaging, thus prolonging survival until consultation with a more experienced physician. Due to lack of experience in resuscitation of massive hemorrhage, some patients in first-line hospitals die before consulting with the surgeon or transfer to the tertiary hospital. As described above, the application of an MT together with GAC provides a simple, easily understood, and easily taught treatment alternative that can be applied by less experienced clinicians, which is an accessible intervention to increase the survival rate.

The patient in the present case experienced a total blood loss of 12000 mL, equivalent to 2.5 times the volume in a man with a body weight of 60 kg, and received a total blood transfusion volume of approximately 9000 mL. This was the author's first experience with such a case, and to their knowledge, a supermassive hemorrhage and transfusion of this magnitude have not previously been described in the peer-reviewed literature.

The medical personnel at the first-line institution lacked experience with major vascular injury-related treatment and therefore applied MT and GAC only; however, these techniques were able to maintain the patient's blood pressure within a certain range without further decreases. In this case, the combined use of MT and GAC provided a simple and effective method, by which clinicians, who lacked experience with major vascular injury rescue and

suturing techniques could prolong the patient's survival until the arrival of a senior doctor.

The lack of experience led to an inability to determine the appropriate treatment in this case, which may result in the severe blood loss. The administration of a blood product with a low PRBC to FFP ratio, as well as Tranexamic Acid (TXA), is a common feature of a standard MTP (5, 7-9, 15). In addition, a standard MTP includes early transfusion of low rate of a PRBC volume proportional to the FFP and platelets volumes (i.e., 1:1:1 ratio of PRBCs to FFP to platelets) and goal-directed therapy (9), in an attempt to avoid deleterious effects of the lethal triad (i.e., hypothermia, coagulopathy, and acidosis), thereby improving mortality (10). In the present case, the total PRBC: FFP ratio was as high as 4.2:1, and no FFP, platelet, or TXA was administered until the senior physician arrived. Chay et al. (16) reported the implementation of a national 1:1:1 protocol in Singapore, yet achieved actual ratio of 1:0.8:0.8; a study from South Korea (17) applied MTP with actual ratio of 1.5:1:1, which still improved outcomes for major trauma patients. According to the previous studies, MT is also an effective resuscitation for massive exsanguinating, although the 1:1:1 protocol is not rigorously followed.

Regarding hemostasis, interventional radiology can be used alternatively to control life-threatening hemorrhagic sites. However, this technique requires an experienced specialist. Hypotensive resuscitation, the Trendelenburg position, coagulation disorder correction, intraoperative cell salvage therapy, and damage control surgery are also important and effective intervention methods for the recovery of a massive hemorrhage. However, as demonstrated in this successful case, the combination of MT plus intraoperative GAC is a simple and direct intervention that can be performed to reduce a massive hemorrhage and maintain relatively stable hemodynamics for at least one hour. In the present situation, this combination was applied intuitively as a result of the first-line surgeons' lack of experience.

Limitations of this study were as follow: MT in this case was not standard MTP, which not only followed the 1:1:1 protocol strictly, yet also lacked reasonable administration of TXA. Meanwhile, development of a highly responsive and effective MTP simultaneously addresses the need for volume resuscitation, oxygen delivery, and application of vasoactive agents. In addition, subsequent treatments also need an attention, yet the authors are only aware that the patient recovered after hospitalized for about one month and did not follow this case after successful surgery.

In conclusion, the combined application of MT and GAC effectively maintained hemodynamics in a patient with an abdominal aorta injury and thus prolonged the time window for an abdominal aorta repair consultation.

Table 1. Related Clinical Characteristics During the Operation

	Pre-Operation	Before Repair Injuries	After Repair Injuries	Post-Operation
Heart rate, bpm	120	145	115	96
Blood pressure, mmHg	105/66	95/55	116/63	118/69
Blood glucose, mmol/L	-	12.7	13.1	-
Transfusion, RBC, u	-	9.5 u	15 u	11 u
Blood serum, mL	-	0	1000	700
Dopamine	-	-	80 mg	-
0.4 mg/mL noradrenaline	-	-	-	4 mL/h for 20 min, following 7 mL/h for 1 h
Sodium bicarbonate	-	-	-	200 mL

Accordingly, these two interventions can be combined to yield a simple and well-understood treatment plan that requires less training and experience and can be applied even at first-line hospitals lacking experience with major vascular injuries. Furthermore, the successful outcome of this case suggests that even a patient with supermassive blood loss can still be rescued via the transfusion of a similarly massive volume of blood. However, standard MTP and specialized resuscitation techniques is the best option for the treatment of an abdominal aorta injury.

References

- Asensio JA, Forno W, Roldan G, Petrone P, Rojo E, Tillou A, et al. Abdominal vascular injuries: Injuries to the aorta. *Surg Clin North Am.* 2001;**81**(6):1395–416. xiii-xiv. doi: [10.1016/S0039-6109\(01\)80014-1](https://doi.org/10.1016/S0039-6109(01)80014-1). [PubMed: [11766182](https://pubmed.ncbi.nlm.nih.gov/11766182/)].
- Ghazala CG, Green BR, Williams R, Wyatt MG. Endovascular management of a penetrating abdominal aortic injury. *Ann Vasc Surg.* 2014;**28**(7):1790 e9–1790 e11. doi: [10.1016/j.avsg.2014.02.019](https://doi.org/10.1016/j.avsg.2014.02.019). [PubMed: [24561212](https://pubmed.ncbi.nlm.nih.gov/24561212/)].
- Rotondo MF, Schwab CW, McGonigal MD, Phillips G3, Fruchterman TM, Kauder DR, et al. 'Damage control': An approach for improved survival in exsanguinating penetrating abdominal injury. *J Trauma.* 1993;**35**(3):375–82. discussion 382-3. doi: [10.1097/00005373-199309000-00008](https://doi.org/10.1097/00005373-199309000-00008). [PubMed: [8371295](https://pubmed.ncbi.nlm.nih.gov/8371295/)].
- Bickell WH, Wall MJ, Pepe PE, Martin RR, Ginger VF, Allen MK, et al. Immediate versus delayed fluid resuscitation for hypotensive patients with penetrating torso injuries. *N Engl J Med.* 1994;**331**(17):1105–9. doi: [10.1056/NEJM199410273311701](https://doi.org/10.1056/NEJM199410273311701). [PubMed: [7935634](https://pubmed.ncbi.nlm.nih.gov/7935634/)].
- Sperry JL, Ochoa JB, Gunn SR, Alarcon LH, Minei JP, Cuschieri J, et al. An FFP:PRBC transfusion ratio 1:1.5 is associated with a lower risk of mortality after massive transfusion. *J Trauma.* 2008;**65**(5):986–93. doi: [10.1097/TA.0b013e3181878028](https://doi.org/10.1097/TA.0b013e3181878028). [PubMed: [19001962](https://pubmed.ncbi.nlm.nih.gov/19001962/)].
- Holcomb JB, Wade CE, Michalek JE, Chisholm GB, Zarzabal LA, Schreiber MA, et al. Increased plasma and platelet to red blood cell ratios improves outcome in 466 massively transfused civilian trauma patients. *Ann Surg.* 2008;**248**(3):447–58. doi: [10.1097/SLA.0b013e318185a9ad](https://doi.org/10.1097/SLA.0b013e318185a9ad). [PubMed: [18791365](https://pubmed.ncbi.nlm.nih.gov/18791365/)].
- Crash- trial collaborators , Shakur H, Roberts I, Bautista R, Caballero J, Coats T, et al. Effects of tranexamic acid on death, vascular occlusive events, and blood transfusion in trauma patients with significant haemorrhage (CRASH-2): A randomised, placebo-controlled trial. *Lancet.* 2010;**376**(9734):23–32. doi: [10.1016/S0140-6736\(10\)60835-5](https://doi.org/10.1016/S0140-6736(10)60835-5). [PubMed: [20554319](https://pubmed.ncbi.nlm.nih.gov/20554319/)].
- Morrison JJ, Dubose JJ, Rasmussen TE, Midwinter MJ. Military application of tranexamic acid in trauma emergency resuscitation (MATTERs) study. *Arch Surg.* 2012;**147**(2):113–9. doi: [10.1001/archsurg.2011.287](https://doi.org/10.1001/archsurg.2011.287). [PubMed: [22006852](https://pubmed.ncbi.nlm.nih.gov/22006852/)].
- Neal MD, Marsh A, Marino R, Kautza B, Raval JS, Forsythe RM, et al. Massive transfusion: An evidence-based review of recent developments. *Arch Surg.* 2012;**147**(6):563–71. doi: [10.1001/archsurg.2011.2212](https://doi.org/10.1001/archsurg.2011.2212). [PubMed: [22786545](https://pubmed.ncbi.nlm.nih.gov/22786545/)].
- Lim G, Harper-Kirksey K, Parekh R, Manani AF. Efficacy of a massive transfusion protocol for hemorrhagic trauma resuscitation. *Am J Emerg Med.* 2018;**36**(7):1178–81. doi: [10.1016/j.ajem.2017.11.060](https://doi.org/10.1016/j.ajem.2017.11.060). [PubMed: [29208320](https://pubmed.ncbi.nlm.nih.gov/29208320/)].
- Riskin DJ, Tsai TC, Riskin L, Hernandez-Boussard T, Purtill M, Maggion PM, et al. Massive transfusion protocols: The role of aggressive resuscitation versus product ratio in mortality reduction. *J Am Coll Surg.* 2009;**209**(2):198–205. doi: [10.1016/j.jamcollsurg.2009.04.016](https://doi.org/10.1016/j.jamcollsurg.2009.04.016). [PubMed: [19632596](https://pubmed.ncbi.nlm.nih.gov/19632596/)].
- Ball CG, Dente CJ, Shaz B, Wyrzykowski AD, Nicholas JM, Kirkpatrick AW, et al. The impact of a massive transfusion protocol (1:1:1) on major hepatic injuries: Does it increase abdominal wall closure rates? *Can J Surg.* 2013;**56**(5):E128–34. [PubMed: [24067528](https://pubmed.ncbi.nlm.nih.gov/24067528/)]. [PubMed Central: [PMC3788022](https://pubmed.ncbi.nlm.nih.gov/PMC3788022/)].
- De Castro GP, Dowling MB, Kilbourne M, Keledjian K, Driscoll IR, Raghavan SR, et al. Determination of efficacy of novel modified chitosan sponge dressing in a lethal arterial injury model in swine. *J Trauma Acute Care Surg.* 2012;**72**(4):899–907. doi: [10.1097/TA.0b013e318248baa1](https://doi.org/10.1097/TA.0b013e318248baa1). [PubMed: [22491602](https://pubmed.ncbi.nlm.nih.gov/22491602/)].
- Baylis JR, St John AE, Wang X, Lim EB, Statz ML, Chien D, et al. Self-propelled dressings containing thrombin and tranexamic acid improve short-term survival in a swine model of lethal junctional hemorrhage. *Shock.* 2016;**46**(3 Suppl 1):123–8. doi: [10.1097/SHK.0000000000000646](https://doi.org/10.1097/SHK.0000000000000646). [PubMed: [27206277](https://pubmed.ncbi.nlm.nih.gov/27206277/)]. [PubMed Central: [PMC4975977](https://pubmed.ncbi.nlm.nih.gov/PMC4975977/)].
- Maciel JD, Gifford E, Plurad D, de Virgilio C, Bricker S, Bongard F, et al. The impact of a massive transfusion protocol on outcomes among patients with abdominal aortic injuries. *Ann Vasc Surg.* 2015;**29**(4):764–9. doi: [10.1016/j.avsg.2014.11.024](https://doi.org/10.1016/j.avsg.2014.11.024). [PubMed: [25725276](https://pubmed.ncbi.nlm.nih.gov/25725276/)].
- Chay J, Koh M, Tan HH, Ng J, Ng HJ, Chia N, et al. A national common massive transfusion protocol (MTP) is a feasible and advantageous option for centralized blood services and hospitals. *Vox Sang.* 2016;**110**(1):36–50. doi: [10.1111/vox.12311](https://doi.org/10.1111/vox.12311). [PubMed: [26178308](https://pubmed.ncbi.nlm.nih.gov/26178308/)].
- Hwang K, Kwon J, Cho J, Heo Y, Lee JC, Jung K. Implementation of trauma center and massive transfusion protocol improves outcomes for major trauma patients: A study at a single institution in Korea. *World J Surg.* 2018;**42**(7):2067–75. doi: [10.1007/s00268-017-4441-5](https://doi.org/10.1007/s00268-017-4441-5). [PubMed: [29290073](https://pubmed.ncbi.nlm.nih.gov/29290073/)].