



# Effectiveness of Uniportal VATS as the First Line Treatment in Early Stage Empyema: A Single Center Clinical Experience

Gökçen Sevilgen<sup>1,\*</sup>, Hasan Türüt<sup>2</sup> and Kerim Tülüce<sup>1</sup>

<sup>1</sup> MD, Assistant Professor of Thoracic Surgery. Recep Tayyip Erdogan University, Faculty of Medicine, Department of Thoracic Surgery, Rize, Turkey

<sup>2</sup> MD, Professor of Thoracic Surgery. Recep Tayyip Erdogan University, Faculty of Medicine. Department of Thoracic Surgery, Rize, Turkey

<sup>3</sup> MD, Assistant Professor of Thoracic Surgery. Recep Tayyip Erdogan University, Faculty of Medicine. Department of Thoracic Surgery, Rize, Turkey

\* **Corresponding author:** Gökçen Sevilgen, Recep Tayyip Erdogan University, Faculty of Medicine, Department of Thoracic Surgery, Rize, Turkey (in Turkish: Recep Tayyip Erdoğan Üniversitesi Tıp Fakültesi, İslampasha, Şehitler Cd. Merkez, Rize, Türkiye. Tel: +905336973147; Email: gsevilgen@gmail.com)

Received 2021 December 26; Revised 2022 February 11; Accepted 2022 March 31.

## Abstract

**Background:** Development of multiloculation and septation in complicated parapneumonic pleural effusion (PPE) may lead to difficult treatment. The studies pointed out that as fibrinolytic therapy might have the potential of complications and a time consuming character, so we should change our management strategy in such patients.

**Objectives:** In this study, we aimed to investigate whether or not uniportal video-assisted thoracoscopic surgery (UVATS) is an initial effective therapy based on clinical and radiologic manifestations.

**Methods:** In this retrospective study, sixty patients who underwent UVATS as the initial intervention with the diagnosis of multiloculated PPE were evaluated between 2016-2019. The patients comorbidities, ASA scores, durations of hospital stay and tube thoracostomy, rate of thoracotomy/decortication, the type of pleural fluid cell and also broad-spectrum antibiotic use, culture results, % neutrophil (NE) ratio with other biochemical parameters before and after VATS were recorded and analyzed.

**Results:** Of the patients, 46 of them (77%) underwent UVATS and a subsequent second port incision was inserted in 14 patients. Shortening of broad-spectrum antibiotic use after VATS was found to be statistically significant in the patients underwent early VATS ( $p < 0.05$ ). We found a statistically significant decrease in the rate of NE % after VATS ( $p < 0.05$ ), that is consistent with the clinical and radiological improvements. The radiological improvement was detected in 96.6% of the patients.

**Conclusion:** We conclude that early UVATS without prior tube thoracostomy is a simple, effective and reliable method as the first-line treatment in patients with complicated PPE. It also confirms that earlier administration of UVATS and more aggressive therapy in the proper indications offers better clinical results.

**Keywords:** Empyema, Multiloculation and Septation, VATS

## 1. Background

Parapneumonic pleural effusion (PPE) is defined as fluid accumulation in the pleural space due to pulmonary infections. It is observed in 57% of bacterial pneumonia and 10% of them require drainage. Complicated PPE is the infection of parapneumonic pleural fluid with bacteria or other microorganisms and pus accumulation in the pleural space. This condition is due to pneumonia and occurs in a considerable rate of such patients (1-4).

Complicated PPE and empyema are conditions that do not regress with antibiotics and require surgical intervention. Regarding the accumulation of fibrin during the fibrino-purulent stage; multiloculation and septation develops and leads to prolonged hospital stay and increased mortality (5). At this stage, the interventions such as tube thoracostomy, intrapleural fibrinolytic therapy (IPFT), video-assisted thoracoscopic surgery (VATS) is applied for deloculation and rarely thoracotomy decortication are used as a therapeutic option (2,3). Previous studies carried out aimed to analyze the efficacy of IPFT and VATS

deloculation, pointed out similar results in terms of clinical and radiological outcomes. However, VATS technique was associated with shorter thoracic catheterization and hospital stay (6). On the other hand, drainage and IPFT even with tissue plasminogen activator (tPA) and Deoxyribonuclease (DNase) can fail in approximately 30% of patients (7).

It is no longer clear that IPFT is time-consuming and potentially complicative technique (28,29,30). On the other hand, in recent years in our country access to fibrinolytic agents for clinical practice is reduced. Above all, improvement and attainability of the minimal invasive techniques almost in every clinic is a known fact, so we started to perform a newly approach in patients with complicated PPE just as diagnosed by the chest physicians.

## 2. Objectives

In this study, we investigated the effectiveness of UVATS deloculation with pleurectomy/decortication as the first line management method without prior tube thoracostomy in the patients with complicated PPE with multiloculation and septation.

### 3. Methods

From 2016, we started to perform UVATS as the primary treatment option in the cases with complicated parapneumonic pleural effusions (PPE) in our clinic. The indication of primary administration of UVATS in the patients with complicated PPE was mainly based on the clinical status as well as the radiologic findings. The patients showing the classical symptoms of PPE with/without toxic status/fewer and accompanying a septated pattern in USG/CT, associated with an unsuccessful thoracentesis basically built our case pool and included in our study.

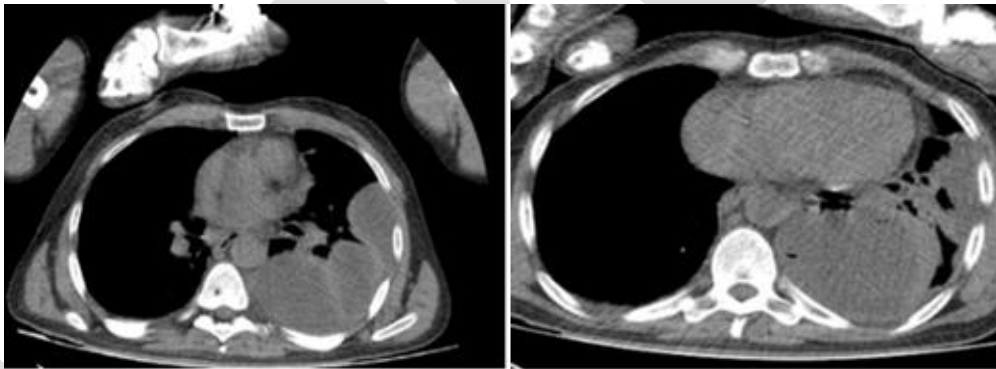
A total of 60 patients with the diagnosis of complicated PPE showing septation and multiloculation whom underwent VATS deloculation and/or decortication as the first line treatment method were included in this study. These results were retrieved and analyzed retrospectively between 2016 and 2019. The patients with advanced stage empyema which needed to thoracotomy decortication were excluded from the study.

In our study, fifteen patients were female and 45 were male with the average age of 53 (Mean±SD= 53±16). In all patients, thoracic computerized

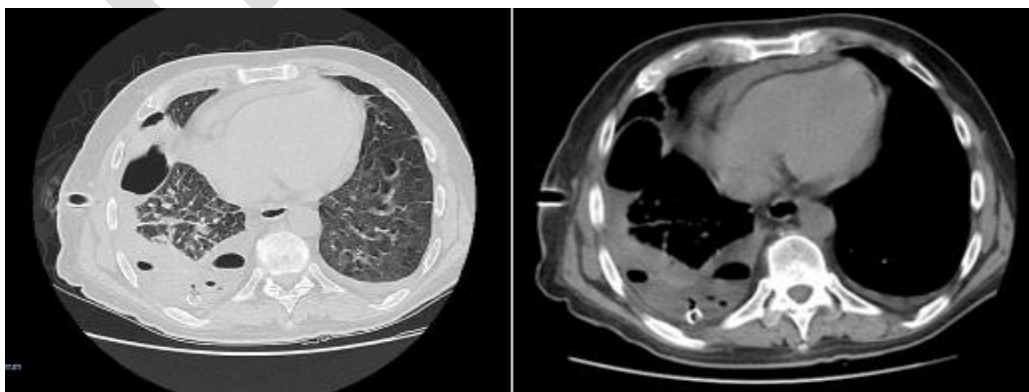
tomography (CT) scan, thoracic USG and thoracentesis were performed before the procedure (Figure 1, 2). The thoracentesis biochemical analyzes were conducted 10-14 days after the first complaints of study participants including: pleural fluid pH<7.2, LDH>1000 IU/L and glucose <60mg/dl, and leukocyte count>100,000 in cell count/mm<sup>3</sup>, polymorphonuclear leukocyte dominance were detected and the findings were compatible with complicated parapneumonic pleural effusion.

During thoracic USG and CT scan when septation and multiloculation (Figure 3, 4, and 5) were observed as soon as the port incision area was marked for the optimal entrance for the intended VATS procedure. All of the patients were followed-up for an average of 22 months.

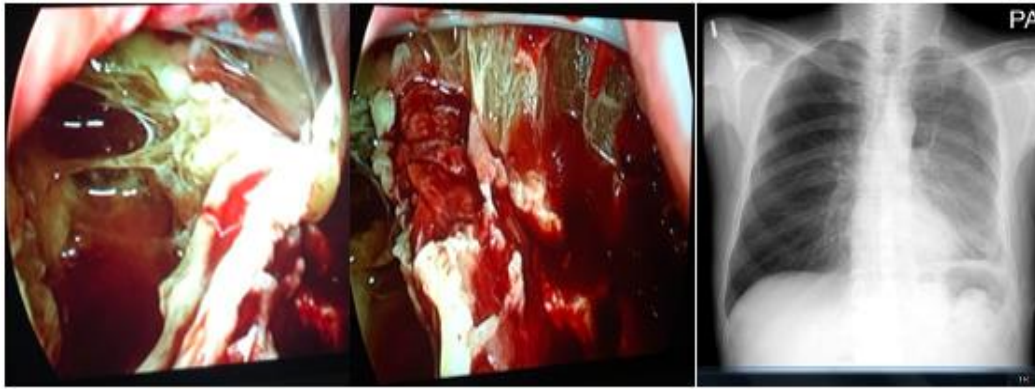
In addition to the demographic characteristics of the patients; co-morbidities, ASA scores, hospital durations after VATS, tube thoracostomy duration after the procedure, prescribed broad-spectrum antibiotic pre and post VATS, serum white blood cell count (WBC), C-reactive protein (CRP), serum calcium (Ca) and potassium (K) values, neutrophil ratio (NE%) and pleural fluid cell count were recorded (Tables 1, 4). A statistical comparison was made between serum WBC, NE %, CRP, calcium



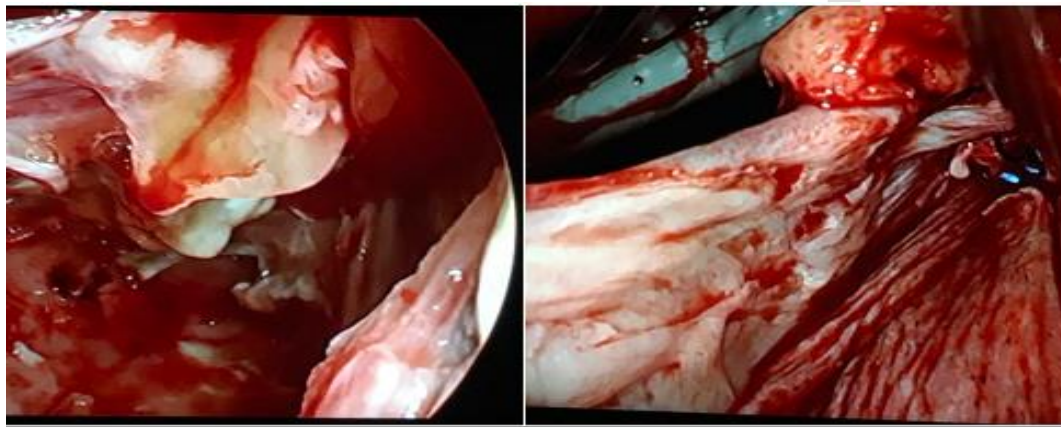
**Figure 1.** A-B: Preoperative CT of the patient treated with VATS. VATS: Videoassisted thoracoscopic surgery; CT: Computed tomography



**Figure 2.** A-B: Preoperative CT of the patient treated with VATS. VATS: Video assisted thoracoscopic surgery; CT: Computed tomography



**Figure 3.** Intraoperative (VATS) septation and multiloculation of the patient (A-B) and postoperative chest radiography (C)



**Figure 4.** Intraoperative (VATS) Empeyema Photos

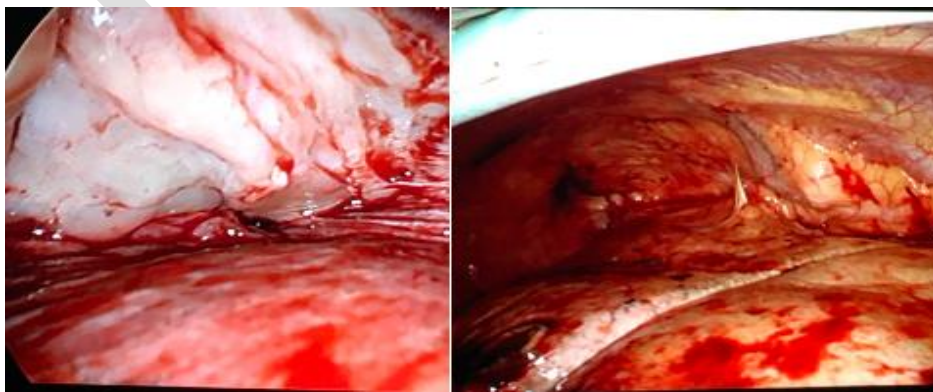
(Ca) and potassium (K) values of the patients before and after VATS procedure.

In 75% (n= 46) of the patients, UVATS procedure was performed and a second port incision was made in 14 patients, subsequently. Awake VATS performed in two patients and just one patient required thoracotomy/decortication (%1,66). In whom visceral pleura wrapped the lung as a very thick layer preventing its expansion as the intraoperative finding and considered to be ineffective and recovered with VATS.

The success rates of the procedure were

compared based on the need of decortication via thoracotomy. Additionally it was defined as the resolution of empyema with reexpansion of lungs in radiographic imaging (Figure 3C), the absence of sepsis, and no need to additional drainage procedures.

During follow-ups in the first and 3<sup>rd</sup> month-visit, we routinely checked the last status of the pleura (in terms of checking the pleural thickening) by the means of contrast enhanced thorax CT scan. Also, radiologically abnormal findings such as thoracic asymmetry and elevation of the diaphragm were the



**Figure 5.** Intraoperative (VATS) View; Thickness visceral pleura and end of the decortication

**Table 1.** Demographic Characteristics of Patients

Patients (N=60)	N	(%)
<b>Age (mean)</b>	56 (53±16)	100
Male	45	73.3
Female	15	26.7
<b>COPD</b>	11	19.6
<b>Cigarette</b>	17	30.4
<b>Use of Antiaggregant and Anticoagulant</b>	10	17.8
ASA 1	2	3.6
ASA 2	20	36.4
ASA 3	28	43.6
ASA 4	10	18.2

ASA: American Society of Anesthesiologists  
COPD: Chronic obstructive pulmonary disease

**Table 2.** Comorbidities of patients

	N	%
<b>Malignancy</b>	5	8.9
<b>Aortic Injury</b>	1	1.8
<b>Chronic Kidney Disease</b>	2	3.5
<b>Pulmonary Embolism</b>	2	3.5
<b>Autoimmune Disease</b>	3	5.3
<b>Tuberculosis</b>	1	1.8

other criteria as well as the pleural thickening depicting the residual disease requiring decortication.

### 3.1. Statistical Analysis

The continuous variables in this study were indicated by means and standard deviations, and categorical data were presented by numbers and

percentages. Mann-Whitney U test was used to evaluate the difference between pre- and post-operative blood values of the patients. The duration of antibiotic use of the patients before and after VATS was evaluated with the repeated measures ANOVA test. The statistical significance level was accepted as p-value less than 0.05.

**Table 3.** Results

	Patients (N=60) (100%)
<b>General Anesthesia</b>	58
<b>Awake Patient</b>	2
<b>Uniportal</b>	46 (77%)
<b>Thoracotomy</b>	1
<b>Hospitalization Duration (Days Mean)</b>	12
<b>Antibiotic Use Before VATS (Days)</b>	11
<b>Antibiotic Use After VATS (Days)</b>	8 (P<0.05)
<b>Total Drainage Amount (Mean)</b>	580 ml
<b>Heimlich Valve Use</b>	17 (31%)
<b>Active Digital Suction System</b>	5 (9%)
<b>Radiological Improvement</b>	58 (96.6%)
<b>Pleural Fluid Culture Reproduction</b>	4 (7.2%)
<b>Tuberculosis Culture or Histopathology</b>	6 (10.8%)
<b>Tube Thoracostomy Durations (Mean)</b>	9 days

**Table 4.** Group (N=60) p Value

	Preop	Postop	p Value
<b>WBC (10<sup>3</sup>/uL)</b>	9,27 (mean)	7,36 (mean)	p > 0.05
<b>NE (%)</b>	78%	64%	p < 0.05
<b>CRP (mg/L)</b>	14	5	p < 0.05
<b>Ca (mg/dl)</b>	8.6	8.4	p > 0.05
<b>K (mmol/L)</b>	4.6	4.4	p > 0.05

WBC: White Blood Cell, NE: Neutrophil Ratio, CRP: C-Reactive Protein,  
Ca: Serum Calcium Level, K: Serum Potassium Level

## 4. Results

In four of the patients (% 6,6) Gram positive cocci,

enterococcus and coagulase negative staphylococcus were detected in the pleural fluid microbiological culture; no growth were observed in the samples of

other patients. The average duration of broad-spectrum double and even triple antibiotic use before VATS was eleven days whereas this value was calculated as eight days in the patients underwent early VATS. The p-value related to the difference between the duration of antibiotic use before and after VATS procedure was calculated as 0.01. The shortening of duration of broad-spectrum antibiotic use after VATS was also found to be statistically significant ( $p < 0.05$ ).

Although, our patients were predominantly placed in the ASA III group (43%), any serious complications related to cardiac, respiratory and/or systemic pathology that would cause postoperative morbidity or mortality were not observed after VATS procedure, similarly no mortality occurred.

Analyzing the differences in WBC, CRP, Ca and K values of the patients before and after the VATS procedure and were not statistically significant. But, our findings showed a statistically significant decrease in NE% ratio ( $p < 0.05$ ) and preoperative neutrophil ratio that was calculated as 78%, following VATS, its rate dramatically reduced in average to 64%.

The duration of tube thoracostomy in patients with complicated PPE was about nine days with an average hospital stay of 12 days. Active digital suction system was to be used in five patients (9%) for the unexpected postoperative space and/or air leakage.

A total of 17 (31%) patients were discharged with Heimlich valve because of pleural fluid drainage of 200-300 ml per day and minimal intrathoracic sterile space. All the remaining patients were discharged upon drainage was terminated and removed. There was no major complications and mortality at the postoperative follow-up. In postoperative histopathological examination and tuberculosis culture results, unexpected malignancy was diagnosed in five patients (9%) referring to oncology department for adjuvant treatment. Besides, tuberculosis reported in six patients (10.8%) and anti-tuberculosis treatment was administered by pulmonologists. In short and long-term follow-ups after VATS, the radiological imaging presented an improvement in 96.6% of the patients (Table 3).

## 5. Discussion

Pleural effusion occurs in 57% of bacterial pneumonias and becomes complicated in 10% of cases (4). The treatment of complicated PPE is widely done by drainage and tube thoracostomy is commonly used as the initial method for this purpose. Antibiotics alone are rarely successful and can be justified only in specific circumstances. Early drainage with or without intrapleural fibrinolytics is usually required (13).

Despite tube thoracostomy, the total drainage of

the pleural effusion can not be achieved in the presence of multiloculation and septation due to fibrin deposition during the fibrino-purulent stage of parapneumonic effusion course. In the patients with complicated PPE, fibrin deposits are seen after inflammatory products, inadequate treatment, and cause mortality, morbidity and an increase in the duration of hospital admission (5). In such patients, it is reported that intrapleural fibrinolytic therapy should be preferred together with VATS and/or tube thoracostomy and is the most effective treatment (2, 7, 9, 10). In the literature review, some studies suggested that VATS procedure as a minimal invasive management is the best option for most patients. Similarly, many studies suggested the superiority of VATS or thoracotomy over simple drainage techniques (19, 26, 27).

In a large retrospective study on 420 patients conducted by Tong, the VATS decortication was demonstrated as safe and effective method with functional results comparable to thoracotomy decortication (13). Similarly, Shrestha et al., enrolled 37 patients to his study in which VATS was conducted in early and late empyema conditions and he demonstrated that it was beneficial for such patients (14). The European Association of Cardio-Thoracic Surgery (EACTS) concluded that VATS has an important role in the management of pleural empyema because of its safety and effectiveness both in stage II and stage III of this condition (15).

Similarly, Wozniak et al. commented that their findings strongly suggested that early and aggressive management provided the better outcomes for the patients, especially those with empyema that is a clinically advanced stage of PPE (7). In our clinic, from 2016 we started to perform UVATS as the initial treatment option in complicated PPEs. Our indication of primarily use of UVATS in the patients with complicated PPE was mainly based on the clinical status as well as the radiological appearance of the patients. The patients showing the classical symptoms of PPE with/without toxic status/fever and had an accompanying septated pattern in USG/CT scans were associated with an unsuccessful thoracentesis, basically builded our case pool. Such patients emergently admitted to the operating room, sometimes on the same day for UVATS not tube thoracostomy. So, we did not need to prescribe any fibrinolytic drugs. As direct VATS deloculation and removal of fibrin membranes with decortication showed the same/more successful effectiveness. We minimized the risk of possible side effects of any fibrinolytic agent as well as the possible longer hospital stay by rapidly conducting this procedure.

Thoracic USG is a safe and simple diagnostic method in complicated PPE that is very sensitive in detecting the septations in the pleural fluid (31). Meanwhile, thoracic USG have advantages over CT

scan, including absence of radiation exposure, non-invasiveness and identification of the distribution of pleural fluid, especially the presence of loculations and septation. Moreover, it permits a guide to detect the most optimal pleural space for port incision before VATS procedure.

Additionally, thoracic USG patterns is well corresponded with intraoperative pleural findings and presents the prognosis of the condition (16). In our cases we used routine thoracic USG in all our patients in order to confirm the septation and also determine the appropriate port placement for UVATS. In the light of our experience, we commit that rapid bedside thoracic USG might solely provide us the opportunity to make a quick decision for early VATS instead of implementation of tube thoracostomy.

In the literature review, the surgical series on complicated PPE have generally focused on the rate of intraoperative conversion from VATS decortication to open thoracotomy. In the retrospective study of Solaini et al., VATS was performed as the first choice in 110 patients in the treatment of advanced stage empyema, and the need for thoracotomy was shown to be significantly reduced in long-term follow-up (17). Schweigert et al. reported a conversion rate of 13% in 335 stage I, II and III empyema patients and this rate in a study by Reichert et al. was reported 5% in 110 cases (18,19).

Lardinois et al. clearly demonstrated that the probability of conversion to thoracotomy for fibrinopurulent empyema increased from 22 % to 86 % between day 12 and 16 of clinical presentation (20). In our study, the need for thoracotomy among sixty cases was seen only in one case in early phase. None of our patients required thoracotomy and decortication in the long term follow ups. The relatively low rate of thoracotomy might be related to early conducting of VATS in the PPE patients. "Early decision" is sometimes so called as "same day VATS" as soon as consulted for consideration by our surgery team for need to elective VATS. On the other hand, our findings revealed that the decision of conversion to thoracotomy and open decortication should be made during the VATS procedure in the early period.

Case series studies of VATS in empyema cases, reported success rates of between 75 and 91%, with better results in free-flowing type, compared with organized empyema (6,32,33). The success rate of VATS was 86.3% in 234 cases in a study by Shi-Ping Luh, and he demonstrated that early intervention in empyema and complicated PPE was related to this appropriate success rate (21).

Overall treatment success rates (no death, no need to additional drainage procedures) among such patients for VATS was 81% in Wozniak et al. study (7). Chung et al. in their recent retrospective analysis of 120 cases of VATS empyemectomies, confirmed the importance of early referral to surgery department of these cases, also demonstrating that

patients with clinical manifestations under four weeks had better early results compared with those reporting longer presentations (22). The Karnofsky Performance Status (KPS) also seems as a strong predictor of overall treatment failure or mortality, nonetheless, and it is reported as a strong and independent predictor for selection of the first choice procedure to treat the empyema.

Similar conclusions were obtained in a study by Stefani et al., who demonstrated that the probability of thoracotomy increased from 28%, when the operation was performed within ten days of the onset of symptoms, while this rate elevated to 81% when it was performed with 30–40 days delay (23). Kho et al. reported that after standalone VATS debridement, the initial size of the cavity decreased to about the sixty percent of the initial cavity size (24). In our study, the success rate was calculated as 96.6%. Our results were considerably high in comparison with the literature, interrelating to the fact that minimising the interval from the onset of the symptoms and the decision of the surgery is crucial.

In another study, 24 patients who underwent VATS due to empyema, the reduction in the duration of hospital stay was found to be statistically significant (8). In study of Wozniak et al. the hospital stays were 12.9, 16.0, and 20.7 days, respectively, for stage I, IIA, and IIB empyema conditions (7).

In a study by Schweigert M et al., the results of empyema treatment were compared with success and failure rates using univariate analysis. In this study, the significant predictors of "overall treatment success," were defined as no death and no further drainage procedures, including the KPS, Charlson comorbidity index, and choice of the first procedure (simple drainage vs. operation) (19).

In our study, age was not an independent predictor of overall treatment failure or death. On the other hands, the shortening of broad-spectrum antibiotic use after VATS was found to be statistically significant ( $p < 0.05$ ). After VATS procedure we found out a statistically significant reduction in NE%, whereas other biochemical parameters did not show a significant statistical difference. Our results revealed that NE% parameter might be the best early predictor of successful treatment.

In postoperative histopathological examination and tuberculosis culture results, unexpected malignancies were diagnosed in five patients (9%) They referred to oncology for adjuvant treatment. Moreover, tuberculosis was detected in six patients (10.8%) and anti-tuberculosis treatment administered for them by pulmonologists.

## 6. Conclusion

Uniportal VATS seems to be an effective treatment method in the patients with empyema with a low risk of need to further thoracotomy in order to avoid

unnecessary extension of the operation time, the probable complications. Moreover, it also might annihilate the need of fibrinolytic drugs. Due to our results, we recommend uniportal VATS as the first line treatment option in the early stage for management of multiloculated complicated PPE.

## Acknowledgments

We would like to thank the Dr. Gökhan Telatar from Recep Tayyip Erdogan University Medical Faculty, department of Public Health, who helped us in the statistical analysis of our data in our study.

## Footnotes

**Conflicts of Interest:** All of authors state there are no conflict of interests in the present study.

**Author's contribution:** Gökçen Sevilgen: conceived the project, collected the data, and wrote the draft of the paper.

Hasan Türüt: designed and supervised the project and edited final proof, the final version.

Kerim Tülüce: participated in data analysis and consulted its integrity.

## Funding/support: ??

**Ethical statement:** This study was approved by the Recep Tayyip Erdogan University Medical Faculty Clinical Research Ethics Committee (Date: 23.09.2020, decision no: 2020/191).

## References

- Light RW. Parapneumonic effusions and empyema. *Proc Am Thorac Soc.* 2006;3(1):75–80. doi: [10.1513/pats.200510-113JH](https://doi.org/10.1513/pats.200510-113JH). [PubMed: [16493154](https://pubmed.ncbi.nlm.nih.gov/16493154/)].
- Maskell NA, Davies CW, Nunn AJ, Hedley EL, Gleeson FV, Miller R, et al. U.K. Controlled trial of intrapleural streptokinase for pleural infection. *N Engl J Med.* 2005;352(9):865–74. doi: [10.1056/NEJMoa042473](https://doi.org/10.1056/NEJMoa042473). [PubMed: [15745977](https://pubmed.ncbi.nlm.nih.gov/15745977/)].
- Tuncozgun B, Elbeyli L. Surgical treatment of parapneumonic empyema. *Turk Thorac J.* 2002;3(6):23–6.
- Koegelenberg CFN, Diacon AH, Bolliger CT. Parapneumonic pleural effusion and empyema. *Respiration.* 2008;75(3):241–50. doi: [10.1159/000117172](https://doi.org/10.1159/000117172). [PubMed: [18367849](https://pubmed.ncbi.nlm.nih.gov/18367849/)].
- Okumus NG, Karaosman S, Kiyani E, İşsever H, Arseven O. Efficacy of intrapleural streptokinase in complicated pleural effusions and empyema. *Turk Thorac J.* 2010;11(1):10–3.
- Godfrey MS, Bramley KT, Detterbeck F. Medical and Surgical Management of Empyema. *Semin Respir Crit Care Med.* 2019;40(3):361–74. doi: [10.1055/s-0039-1694699](https://doi.org/10.1055/s-0039-1694699). [PubMed: [31525811](https://pubmed.ncbi.nlm.nih.gov/31525811/)].
- Wozniak CJ, Paull DE, Moezzi JE, Scott RP, Anstadt MP, York VV, et al. Choice of first intervention is related to outcomes in the management of empyema. *Ann Thorac Surg.* 2009;87(5):1525–30. doi: [10.1016/j.athoracsur.2009.01.028](https://doi.org/10.1016/j.athoracsur.2009.01.028). [PubMed: [19379898](https://pubmed.ncbi.nlm.nih.gov/19379898/)].
- Powell LL, Allen R, Brenner M, Aryan HE, Chen JC. Improved patient outcome after surgical treatment for loculated empyema. *Am J Surg.* 2000;179(1):1–6. doi: [10.1016/s0002-9610\(99\)00262-7](https://doi.org/10.1016/s0002-9610(99)00262-7). [PubMed: [10737568](https://pubmed.ncbi.nlm.nih.gov/10737568/)].
- Anstadt MP, Guill CK, Ferguson ER, Gordon HS, Soltero ER, Beall AC, et al. Surgical versus nonsurgical treatment of empyema thoracis: an outcomes analysis. *Am J Med Sci.* 2003;326(1):9–14. doi: [10.1097/0000441-200307000-00002](https://doi.org/10.1097/0000441-200307000-00002). [PubMed: [12861120](https://pubmed.ncbi.nlm.nih.gov/12861120/)].
- Light RW. A new classification of parapneumonic effusions and empyema. *Chest.* 1995;108(2):299–301. doi: [10.1378/chest.108.2.299](https://doi.org/10.1378/chest.108.2.299). [PubMed: [7634854](https://pubmed.ncbi.nlm.nih.gov/7634854/)].
- Villena Garrido V, Cases Viedma E, Fernández Villar A, de Pablo Gafas A, Pérez Rodríguez E, Porcel Pérez JM, et al. Recommendations of diagnosis and treatment of pleural effusion. Update. *Arch Bronconeumol.* 2014;50(6):235–49. doi: [10.1016/j.arbr.2014.04.007](https://doi.org/10.1016/j.arbr.2014.04.007).
- Zuckerman DA, Reed MF, Howington JA, Moulton JS. Efficacy of intrapleural tissue-type plasminogen activator in the treatment of loculated parapneumonic effusions. *J Vasc Interv Radiol.* 2009;20(8):1066–9. doi: [10.1016/j.jvir.2009.04.067](https://doi.org/10.1016/j.jvir.2009.04.067). [PubMed: [19560940](https://pubmed.ncbi.nlm.nih.gov/19560940/)].
- Tong BC, Hanna J, Toloza EM, Onaitis MW, D'Amico TA, Harpole DH, et al. Outcomes of video-assisted thoracoscopic decortication. *Ann Thorac Surg.* 2010;89(1):220–5. doi: [10.1016/j.athoracsur.2009.09.021](https://doi.org/10.1016/j.athoracsur.2009.09.021). [PubMed: [20103240](https://pubmed.ncbi.nlm.nih.gov/20103240/)].
- Shrestha UK, Thapa B, Baral R. Videothoracoscopic management of empyema thoracis in tertiary level thoracic unit. *J Inst Med.* 2013;35:11–3.
- Scarci M, Abah U, Solli P, Page A, Waller D, van Schil P, et al. EACTS expert consensus statement for surgical management of pleural empyema. *Eur J Cardiothorac Surg.* 2015;48(5):642–53. doi: [10.1093/ejcts/ezv272](https://doi.org/10.1093/ejcts/ezv272). [PubMed: [26254467](https://pubmed.ncbi.nlm.nih.gov/26254467/)].
- Bongiolatti S, Voltolini L, Borgianni S, Borrelli R, Tancredi G, Viggiano D, et al. Uniportal thoracoscopic decortication for pleural empyema and the role of ultrasonographic preoperative staging. *Interact Cardiovasc Thorac Surg.* 2017;24(4):560–6. doi: [10.1093/icvts/ivw423](https://doi.org/10.1093/icvts/ivw423). [PubMed: [28108575](https://pubmed.ncbi.nlm.nih.gov/28108575/)].
- Solaini L, Prusciano F, Bagioni P. Video-assisted thoracic surgery in the treatment of pleural empyema. *Surg Endosc.* 2007;21(2):280–4. doi: [10.1007/s00464-006-0151-z](https://doi.org/10.1007/s00464-006-0151-z). [PubMed: [17122974](https://pubmed.ncbi.nlm.nih.gov/17122974/)].
- Reichert M, Pösentrup B, Hecker A, Schneck E, Pons-Kühnemann J, Augustin F, et al. Thoracotomy versus video-assisted thoracoscopic surgery (VATS) in stage III empyema: an analysis of 217 consecutive patients. *Surg Endosc.* 2018;32(6):2664–75. doi: [10.1007/s00464-017-5961-7](https://doi.org/10.1007/s00464-017-5961-7). [PubMed: [29218675](https://pubmed.ncbi.nlm.nih.gov/29218675/)].
- Schweigert M, Solymosi N, Dubecz A, Fernández MJ, Stadlhuber RJ, Ofner D, et al. Surgery for parapneumonic pleural empyema—what influence does the rising prevalence of multimorbidity and advanced age has on the current outcome?. *Surgeon.* 2016;14(2):69–75. doi: [10.1016/j.surge.2014.05.002](https://doi.org/10.1016/j.surge.2014.05.002). [PubMed: [24930000](https://pubmed.ncbi.nlm.nih.gov/24930000/)].
- Lardinois D, Gock M, Pezzetta E, Buchli C, Rousson V, Furrer M, et al. Delayed referral and gram-negative organisms increase the conversion thoracotomy rate in patients undergoing video-assisted thoracoscopic surgery for empyema. *Ann Thorac Surg.* 2005;79(6):1851–6. doi: [10.1016/j.athoracsur.2004.12.031](https://doi.org/10.1016/j.athoracsur.2004.12.031). [PubMed: [15919270](https://pubmed.ncbi.nlm.nih.gov/15919270/)].
- Luh SP, Chou MC, Wang LS, Chen JY, Tsai TP. Video-assisted thoracoscopic surgery in the treatment of complicated parapneumonic effusions or empyemas: outcome of 234 patients. *Chest.* 2005;127(4):1427–32. [PubMed: [15821225](https://pubmed.ncbi.nlm.nih.gov/15821225/)].
- Chung JH, Lee SH, Kim KT, Jung JS, Son HS, Sun K. Optimal timing of thoracoscopic drainage and decortication for empyema. *Ann Thorac Surg.* 2014;97(1):224–9. doi: [10.1016/j.athoracsur.2013.08.039](https://doi.org/10.1016/j.athoracsur.2013.08.039). [PubMed: [24119984](https://pubmed.ncbi.nlm.nih.gov/24119984/)].
- Stefani A, Aramini B, della Casa G, Ligabue G, Kaleci S, Casali C, et al. Preoperative predictors of successful surgical treatment in the management of parapneumonic empyema. *Ann Thorac Surg.* 2013;96(5):1812–9. doi: [10.1016/j.athoracsur.2013.06.013](https://doi.org/10.1016/j.athoracsur.2013.06.013). [PubMed: [23987892](https://pubmed.ncbi.nlm.nih.gov/23987892/)].
- Kho P, Karunanatham J, Leung M, Lim E. Debridement alone without decortication can achieve lung re-expansion in patients with empyema: an observational study. *Interact Cardiovasc Thorac Surg.* 2011;12(5):724–7. doi: [10.1510/icvts.2010.247619](https://doi.org/10.1510/icvts.2010.247619). [PubMed: [21345817](https://pubmed.ncbi.nlm.nih.gov/21345817/)].
- Samancilar O, Akcam TI, Kaya SO, Ozturk O, Akcay O, Ceylan KC. The Efficacy of VATS and Intrapleural Fibrinolytic Therapy in Parapneumonic Empyema Treatment. *Ann Thorac Cardiovasc Surg.* 2018;24(1):19–24. doi: [10.5761/atcs.0a.17-](https://doi.org/10.5761/atcs.0a.17-)

00153. [PubMed: 29343663].
26. Petrakis IE, Kogerakis NE, Drositis IE, Lasithiotakis KG, Bouros D, Chalkiadakis GE. Video-assisted thoracoscopic surgery for thoracic empyema: primarily, or after fibrinolytic therapy failure?. *Am J Surg.* 2004;**187**(4):471-4. doi: [10.1016/j.amjsurg.2003.12.048](https://doi.org/10.1016/j.amjsurg.2003.12.048). [PubMed: 15041493].
27. Cunniffe MG, Maguire D, McAnena OJ, Johnston S, Gilmartin JJ. Video-assisted thoracoscopic surgery in the management of loculated empyema. *Surg Endosc.* 2000;**14**(2):175-8. doi: [10.1007/s004649900094](https://doi.org/10.1007/s004649900094). [PubMed: 10656955].
28. Gervais DA, Levis DA, Hahn PF, Uppot RN, Arellano RS, Mueller PR. Adjunctive Intrapleural Tissue Plasminogen Activator Administered via Chest Tubes Placed with Imaging Guidance: Effectiveness and Risk for Hemorrhage. *Radiology.* 2008;**246**(3):956-63. doi: [10.1148/radiol.2463070235](https://doi.org/10.1148/radiol.2463070235). [PubMed: 18309017].
29. Chai FY, Kuan YC. Massive hemothorax following administration of intrapleural streptokinase. *Ann Thorac Med.* 2011;**6**(3):149-51. doi: [10.4103/1817-1737.82451](https://doi.org/10.4103/1817-1737.82451). [PubMed: 21760848].
30. Goralski JL, Bromberg PA, Haithcock B. Intrapleural hemorrhage after administration of tPA: a case report and review of the literature. *Thor Adv Respir Dis.* 2009;**3**(6):295-300. doi: [10.1177/1753465809350748](https://doi.org/10.1177/1753465809350748). [PubMed: 19934281].
31. Hassan M, Mercer RM, Rahman NM. Thoracic ultrasound in the modern management of pleural disease. *Eur Respir Rev.* 2020;**29**(156):190136. doi: [10.1183/16000617.0136-2019](https://doi.org/10.1183/16000617.0136-2019). [PubMed: 32350086].
32. Brutsche MH, Tassi GF, Györik S, Gökcimen M, Renard C, Marchetti GP, et al. Treatment of sonographically stratified multiloculated thoracic empyema by medical thoracoscopy. *Chest.* 2005;**128**(5):3303-9. doi: [10.1378/chest.128.5.3303](https://doi.org/10.1378/chest.128.5.3303). [PubMed: 16304276].
33. Ravaglia C, Gurioli C, Tomassetti S, Casoni GL, Romagnoli M, Gurioli C, et al. Is medical thoracoscopy efficient in the management of multiloculated and organized thoracic empyema? *Respiration.* 2012;**84**(3):219-24. doi: [10.1159/000339414](https://doi.org/10.1159/000339414). [PubMed: 22832393].