



# Hydatid Cyst of the Breast: A Case Series and Review of the Literature

Maryam Tavakoli,<sup>1</sup> Yalda Fallah Rastegar,<sup>1</sup> Ali Feyzi Laein,<sup>1</sup> and Donya Farrokh<sup>1,2,\*</sup>

<sup>1</sup>Department of Radiology, Faculty of Medicine, Mashhad University of Medical Sciences, Mashhad, IR Iran

<sup>2</sup>Surgical Oncology Research Center, Mashhad University of Medical Sciences, Mashhad, IR Iran

\*Corresponding author: Donya Farrokh, Surgical Oncology Research Center, Imam Reza Hospital, Faculty of Medicine, Mashhad University of Medical Sciences, Mashhad, IR Iran. Tel: +98-5138020000, Fax: +98-5138525255, E-mail: farrokhd@mums.ac.ir

Received 2015 May 19; Revised 2015 August 03; Accepted 2015 October 03.

## Abstract

**Introduction:** A hydatid cyst of the breast is an extremely rare condition caused by *Echinococcus granulosus*, even in endemic countries, which accounts for 0.27% of all cases. Only a few reports have been published in the literature about breast hydatid cysts. Patients usually present with a palpable and painless lump in the breast. Clinically, it is difficult to differentiate breast hydatid cysts from more common breast lesions. However, imaging plays an important role, and often helps to distinguish this rare cystic disease of the breast from other breast masses.

**Case Presentation:** Iran is an endemic area for *Echinococcus granulosus*, and we present six cases of primary breast hydatid cysts which were diagnosed over the course of 10 years in our institution. We aimed to present the mammographic and ultrasonographic findings for these patients.

**Conclusions:** Hydatid cysts should be considered in the diagnosis of cystic lesions of the breast, particularly in endemic areas.

**Keywords:** Breast, Echinococcosis, Hydatid cyst, Ultrasonography

## 1. Introduction

Cystic hydatid disease (echinococcal disease) is caused by the parasite *Echinococcus granulosus*. The definitive host of the parasite is a dog, whereas the intermediate hosts are usually sheep and other ruminants. Humans are occasional intermediate hosts in whom the parasite could cause hydatid cysts (? , ? ). Hydatid cysts are endemic in some areas of the world, such as Iran. The disease is usually found in the liver (75%) and the lung (15%), but can develop anywhere else in the body (10%), with frequent reports in the kidney, spleen, central nervous system, pancreas, adrenal, peritoneum, soft tissue, and the breast (? -? ). A hydatid cyst of the breast is a rare disease, although it has been reported more frequently in recent years (? , ? ). In differentiating the breast hydatid cyst from other benign and malignant breast masses, some difficulties are encountered. Given the distinct nature of the disease, it should be included in the differential diagnosis of breast lumps, especially in endemic countries (? ). In addition to routine laboratory tests, various radiologic methods are used for identification of the cysts in this unusual localization. Since hydatid disease remains a serious health problem in Iran, we report six cases of cystic hydatid disease of the breast. The mammographic and ultrasonic findings of this rare breast disease are also described.

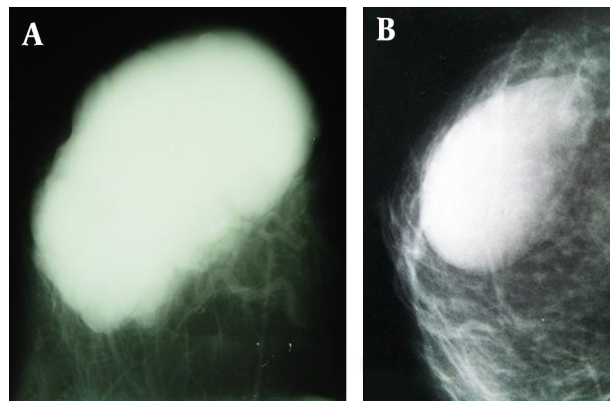
## 2. Case Presentation

This study was conducted in the surgical and radiological departments of Imam Reza Hospital, a part of Mashhad University of Medical Sciences, from June 2000 through September 2012. Six women were diagnosed and confirmed to have breast hydatid disease. The mean age of the patients was 32 (range: 25 - 52) years. The mean duration of symptoms was 18 months (range: 8 months - 3 years). The involvement was unilateral in all patients. The left breast was involved in four cases, and the right breast was affected in two patients. A breast lump was the most common clinical presentation, which was observed in all cases. The breast lump was painless in four cases. Upon physical examination, all breast lumps were determined to be mobile, and there were no associated skin changes or nipple deformities. The mean size of the lumps was 3.5 (range: 2 - 8) cm. There was no history of discharge from the nipple, fever, or breast cancer. The skin and the nipple were normal in all cases, and there were no enlarged lymph nodes in the axilla.

Each patient underwent mammography and ultrasonography. The most common mammographic finding was an oval, well-circumscribed mass with smooth margins and homogeneous density. The largest mass measured about 8 × 6 × 6 cm as a maximum dimension (Fig-

ure 1A). The breast masses displayed the mammographic appearance of a probably benign lesion in all patients (Figure 1B). There was no evidence of commonly associated findings, such as micro calcification, architectural distortion, skin changes, and nipple retraction.

**Figure 1.** Mammographic Appearance of the Breast Hydatid Cyst



A, craniocaudal oblique mammogram image shows a large dense breast mass with well-circumscribed, smooth margins in the left breast; B, medio-lateral mammogram image demonstrates a dense homogeneous mass in the left upper outer quadrant.

Ultrasonography was performed for further characterization of the breast masses using GE Voluson ultrasonography machine. A cystic mass with multiple thick internal septa and echogenic materials was the most common ultrasonographic appearance, which was detected in three cases (Figure 2A and 2B). In one patient, there was evidence of a giant, well-circumscribed cystic mass with multiple hyperechoic band-like structures measuring  $8 \times 7 \times 6.5$  cm, which was suspected to be associated with the occurrence of a hydatid cyst (Figure 2C). In one of the patients, the ultrasonography revealed a cystic mass with echogenic material and a trapped internal membrane, which was also suspected to be indicative of a breast hydatid cyst (Figure 2D). The mammographic and ultrasonographic findings are shown in Table 1.

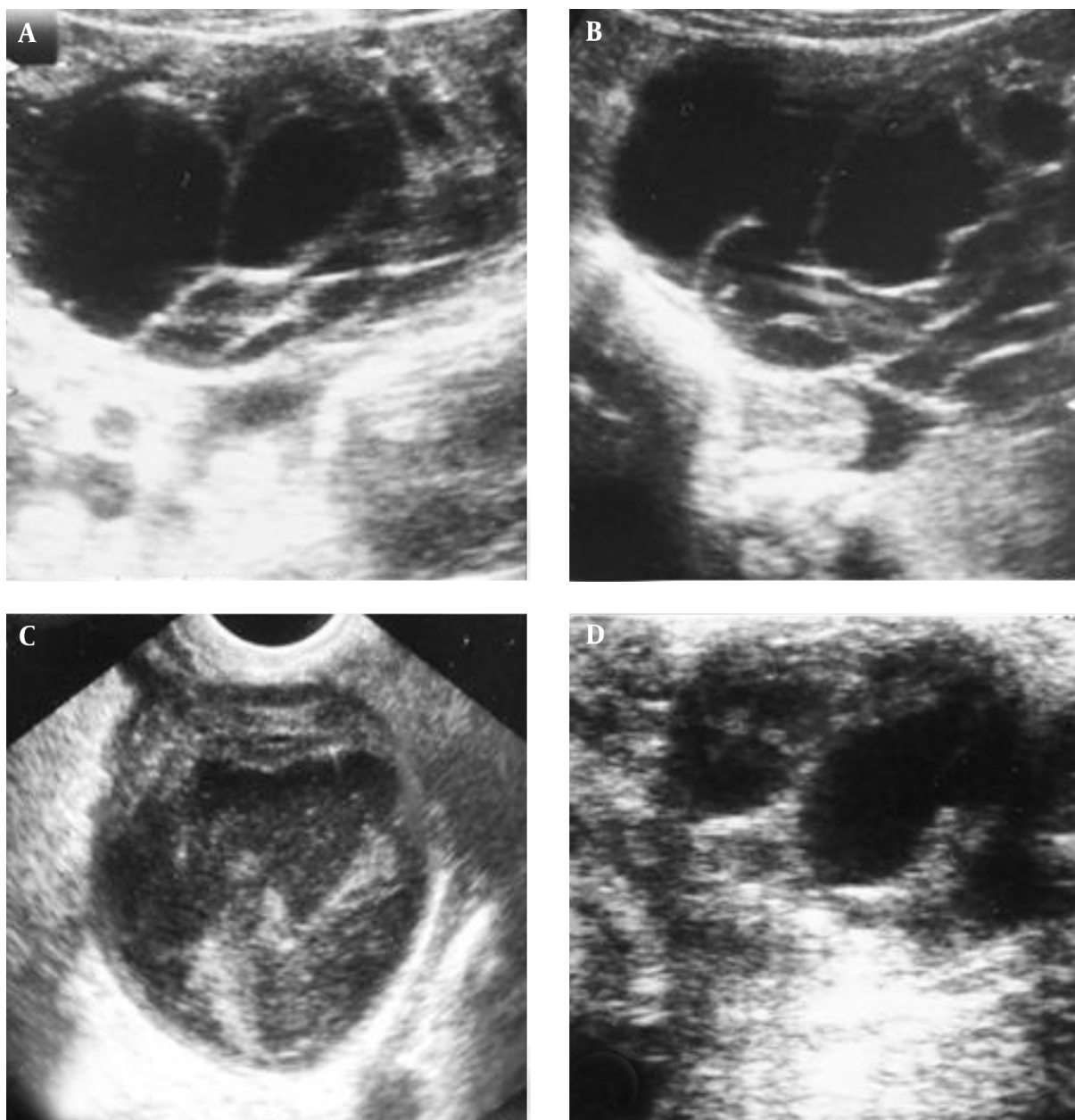
A fine needle aspiration biopsy (FNAB) of the breast was performed in one patient and a core needle biopsy was conducted for two patients. In the pathological analysis, microscopic protoscolices hooklets confirmed the diagnosis of hydatid cyst. In the other three patients, excisional biopsies were performed and pathological analysis of the specimens in these cases revealed scanty material composed of fragmented membranes associated with hooklets, which was consistent with the diagnosis of a hydatid cyst. FNAB was uneventful in these patients. Routine laboratory tests were normal in all patients. The Echinococcal hemagglutination test was performed on four patients, and positive re-

sults were revealed for all of them. The titer of the hemagglutination test was between 1/300 and 1/700 (a hemagglutination test titer  $> 1/100$  is considered to be a positive result). All of the patients were referred to the surgical department and the breast masses were completely excised. The diagnosis of a breast hydatid cyst was confirmed by histological examination in all patients. After surgical resection, patients were treated with Albendazole (10 mg/kg/day) for three months, since it could play a role in decreasing the recurrence rate of the hydatid disease. One of the patients who had a giant breast mass received Albendazole treatment and after eight courses, the ultrasonography showed no significant changes in the size of the mass. For main differential diagnosis, postoperative abdominal ultrasonography, chest radiography, and a thoracoabdominal computed tomography scan were conducted, but they revealed no concomitant hydatid cysts in other locations.

### 3. Discussion

*Echinococcus granularis* is a serious problem in sheep and cattle raising countries. Hydatidosis is an endemic disease observed in many parts of the world, including the Mediterranean countries, South America, Australia, North and East Africa, China, Russia, and the Middle East (? , ? ). Iran is also an endemic area for hydatid disease. The liver and lungs are the most frequently affected organs in humans (? , ? , ? ). Breast hydatid disease may present as an indicator of multi-system involvement or may only indicate the occurrence in one part of the body (? , ? , ? ). The breast is an extremely rare primary site for hydatid disease, even in endemic areas. The reported incidence of hydatid cysts in the breast is 0.27% - 0.37% of all occurrences (? ). Breast hydatid disease usually occurs in females. The age range is variable, but most of the patients are in the third to fifth decades of life (? , ? , ? , ? ). The disease usually presents as a palpable, painless mass which may gradually increase in size over months or years. All of the patients in this study presented with a long history of a breast lump (1-6 years). Consistent with our findings, a review article from Iran from 2013 indicated reports of eight cases of breast hydatid cysts with the most common presentation as a well-defined palpable breast mass (? ).

The main imaging modalities used for the diagnosis of breast hydatid disease are mammography, ultrasonography, and magnetic resonance imaging (MRI), but the ultrasonography is the method of choice for the evaluation of this particular cystic lesion (? , ? , ? ). Mammography usually reveals a hydatid cyst as a well-circumscribed mass of variable density (? , ? , ? ). It may show ring-shaped structures or internal bands within the cyst (? ). The different density of the daughter cyst in the main cyst

**Figure 2.** Ultrasonographic Appearance of the Breast Hydatid Cyst

A and B, Ultrasound image shows a multiloculated cystic mass with thick internal septa and echogenic materials; C, Ultrasound image shows a cystic mass with multiple hyperechoic band-like structures; D, Ultrasound image shows a cystic mass with echogenic material and a trapped internal membrane.

can cause these ring-shaped structures. If there is no evidence of these structures within the mass, then it is usually difficult to distinguish a hydatid cyst from other breast masses, including fibroadenoma, phyllodes tumors, or circumscribed carcinoma (1, 2, 3, 4). Mammography may show a mass with calcification, which must then

be differentiated from a calcified fibroadenoma (5, 6). For the patients in this study, the most common mammographic appearance was an oval well-circumscribed mass with smooth margins and homogeneous density.

Ultrasonography does not easily distinguish hydatid cysts from other simple or complicated cysts of the breast.

**Table 1.** Mammographic and Ultrasonographic Findings in Five Patients with a Breast Hydatid Cyst

Number	Mammographic Findings				Ultrasonographic Findings
	Size (cm)	Shape	Margins	Density	
1	4 × 4 × 3	Round	Lobulate	Homogeneous	A multiloculated cystic mass with thick internal septa and echogenic materials
2	3.5 × 2.5 × 2.5	Oval	Smooth	Homogeneous	A uniloculated cystic mass with heterogeneous internal echoes
3	3 × 3 × 3	Oval	Smooth	Homogeneous	A mass with heterogeneous echogenicity and a cystic component
4	4 × 3 × 3	Round	Smooth	Homogeneous	A cystic mass with multiple internal septa and echogenic material
5	8 × 6 × 6	Oval	Smooth	Non homogeneous	A giant cystic mass with multiple hyperechoic band-like structures
6	2 × 2.5 × 3	Oval	Smooth	Homogeneous	A multiloculated giant cystic mass with thick internal septa and echogenic materials

It usually presents hydatid cysts as uniloculated or multiloculated cystic lesions (? ). However, the hydatid sands, protoscolices, and debris can cause internal echoes (? ). Five ultrasonographic patterns have been described by Gharbi et al., including uniloculated pure fluid collection (type 1), fluid collection with a split wall (type 2), a multivesicular, multiseptated cyst with daughter cysts (type 3), a mass with a heterogeneous echo pattern (type 4), and a mass with reflecting thick walls (type 5) (? ). Durr-e-Sabih et al. described the “congealed water lily sign” appearance for a hydatid cyst of the liver. In these cases, the germinal layer is trapped within the viscid material of the cysts, which gives rise to such an appearance, this is highly suggestive of a diagnosis of a hydatid cyst (? ). Trabelsi et al. also reported this ultrasonic appearance in a breast hydatid cyst (? ). Hydatid sand and fluid of the hydatid cyst in the mammary glands may be detected with ultrasonography. The presence of a cystic lesion in another organ of the body is associated with a multilocular cystic mass showing a fluid level in the breast, suggesting hydatid disease. The most common ultrasonographic appearance in this study was a multiloculated cystic lesion with thick internal septa and echogenic materials. Similarly, ultrasonography of a breast hydatid cyst by Kumar et al. revealed a thick-walled cystic lesion with floating membranes and internal echoes in the subareolar region of the right breast (? ).

MRI findings are usually non-specific but may be helpful in determining the presence of capsular enhancement in a cystic lesion. This capsular enhancement is often seen in an infected cyst, and a hydatid cyst may present as a cystic lesion with no evidence of capsular enhancement. A breast abscess may show similar capsular enhancement; however, in the absence of a positive physical examination for a breast abscess, the presence of a well-circumscribed, cystic breast mass with capsular enhancement should be suggestive of a hydatid cyst (? , ? , ? , ? ). MRI was not used for the patients of this study.

Serologic tests can help to confirm the diagnosis even in the absence of liver or lung involvement or in the follow-

up course (? , ? ). In this study, the serologic tests performed on four patients were positive.

Diagnosis by fine needle aspiration biopsy is controversial. Although not recommended by many authors, FNAB can provide a safe pre-operative diagnosis and may show cuticle-wall structures with a diagnostic appearance, but scolices are less likely to be identified in the aspirated materials (? , ? ). However, demonstration of hooklets is a definitive diagnostic sign of a hydatid cyst (? , ? , ? ). Here, the diagnosis of a hydatid cyst was established by FNAB and confirmed by pathological study in one of the patients. In two cases, the diagnosis of a hydatid cyst was made after core needle biopsy. These patients did not show any significant complications after FNAB or core needle biopsy of the breast lesions, which is consistent with the results of previous studies (? , ? , ? ).

Treatment of breast hydatid disease is based on complete surgical excision and medical therapy with anthelmintic drugs such as Albendazole and Mebendazole (? ). Accidental implantation can be prevented through irrigation of the cyst bed with 3% saline solution (? , ? , ? ). Recurrent hydatid disease in the breast is rare and is treated with surgery and/or additional medical treatment.

In conclusion, hydatid cysts in the breast are rare, but should be included in the differential diagnosis for breast masses, especially in countries where the disease is endemic. As the cysts grow slowly, they are usually confused with cystic lesions due to mammary fibrocystic changes or benign breast masses. When ring-shaped structures are not present, the mammographic findings are not specific. Sonographic features are variable and usually non-specific, and the definitive diagnosis should be confirmed by pathological study.

#### Acknowledgments

We would like to thank our colleagues in the departments of surgery and pathology at Mashhad University of Medical Sciences. The authors would also like to extend



their appreciation to Ms. M. Hassanpour for her contributions in editing the manuscript.

## Footnote

**Authors' Contribution:** Acquisition, analysis and interpretation of the data and drafting of the manuscript: Maryam Tavakoli, Yalda Fallah Rastegar, Ali Feyzi Laein, Donya Farrokh; Study supervision: Donya Farrokh.

## References

- Mujawar P, Suryawanshi KH, Nikumbh DB. Cytodiagnosis of isolated primary hydatid cyst of breast masquerading as a breast neoplasm: A rare case report. *J Cytol*. 2015;**32**(4):270-2. doi: [10.4103/0970-9371.171248](https://doi.org/10.4103/0970-9371.171248). [PubMed: [26811577](https://pubmed.ncbi.nlm.nih.gov/26811577/)].
- Geramizadeh B. Unusual locations of the hydatid cyst: a review from iran. *Iran J Med Sci*. 2013;**38**(1):2-14. [PubMed: [23645952](https://pubmed.ncbi.nlm.nih.gov/23645952/)].
- Engin G, Acunas B, Rozanes I, Acunas G. Hydatid disease with unusual localization. *Eur Radiol*. 2000;**10**(12):1904-12. doi: [10.1007/s003300000468](https://doi.org/10.1007/s003300000468). [PubMed: [11305568](https://pubmed.ncbi.nlm.nih.gov/11305568/)].
- Kiresi DA, Karabacakoglu A, Odev K, Karakose S. Uncommon locations of hydatid cysts. *Acta Radiol*. 2003;**44**(6):622-36. [PubMed: [14616207](https://pubmed.ncbi.nlm.nih.gov/14616207/)].
- Alamer A, Aldhilan A, Mankanjuola D, Alkushi A. Preoperative diagnosis of hydatid cyst of the breast: a case report. *Pan Afr Med J*. 2013;**14**:99. doi: [10.11604/pamj.2013.14.99.2396](https://doi.org/10.11604/pamj.2013.14.99.2396). [PubMed: [23717714](https://pubmed.ncbi.nlm.nih.gov/23717714/)].
- Acar T, Gomcel Y, Guzel K, Yazgan A, Aydyn R. Isolated hydatid cyst of the breast. *Scott Med J*. 2003;**48**(2):52-3. [PubMed: [12774597](https://pubmed.ncbi.nlm.nih.gov/12774597/)].
- Motie MR, Rezapanah A, Pezeshki Rad M, Razavian H, Azadmand A, Khajeh M. Primary localization of a hydatid cyst in the latissimus dorsi muscle: an unusual location. *Surg Infect (Larchmt)*. 2011;**12**(5):401-3. doi: [10.1089/sur.2010.077](https://doi.org/10.1089/sur.2010.077). [PubMed: [22004438](https://pubmed.ncbi.nlm.nih.gov/22004438/)].
- Das DK, Choudhury U. Hydatid disease: an unusual breast lump. *J Indian Med Assoc*. 2002;**100**(5):327-8. [PubMed: [12418637](https://pubmed.ncbi.nlm.nih.gov/12418637/)].
- Erkan N, Hacıyanlı M, Yildirim M, Yılmaz C. A case report of the unusual presence of hydatid disease in the pancreas and breast. *JOP*. 2004;**5**(5):368-72. [PubMed: [15365205](https://pubmed.ncbi.nlm.nih.gov/15365205/)].
- Jabbari Nooghabi A, Raoufian K, Motie MR. Concomitant splenic and hepatic hydatidosis: report of two cases and review of the literature. *Acta Med Iran*. 2015;**53**(1):74-7. [PubMed: [25597610](https://pubmed.ncbi.nlm.nih.gov/25597610/)].
- Tutar N, Cakir B, Geyik E, Tarhan NC, Niron EA. Hydatid cysts in breast: mammography and ultrasound findings. *Br J Radiol*. 2006;**79**(946):114-6. doi: [10.1259/bjr/33156239](https://doi.org/10.1259/bjr/33156239). [PubMed: [16980663](https://pubmed.ncbi.nlm.nih.gov/16980663/)].
- Trabelsi A, Fatnaci R, Ouni F, Rammeh S, Korbi S. Hydatid cyst of the breast: a case report. *Pathologica*. 2008;**100**(3):197-8. [PubMed: [18841828](https://pubmed.ncbi.nlm.nih.gov/18841828/)].
- Koc A, Sarici IS, Vurdem UE. Unusual Presentation of Hydatid Cyst in Breast with Magnetic Resonance Imaging Findings. *Case Rep Med*. 2017;**2017**. 6237435.
- Cancelo MJ, Martin M, Mendoza N. Preoperative diagnosis of a breast hydatid cyst using fine-needle aspiration cytology: a case report and review of the literature. *J Med Case Rep*. 2012;**6**(293). doi: [10.1186/1752-1947-6-293](https://doi.org/10.1186/1752-1947-6-293). [PubMed: [22973941](https://pubmed.ncbi.nlm.nih.gov/22973941/)].
- Gharbi HA, Hassine W, Brauner MW, Dupuch K. Ultrasound examination of the hydatid liver. *Radiology*. 1981;**139**(2):459-63. doi: [10.1148/radiology.139.2.7220891](https://doi.org/10.1148/radiology.139.2.7220891). [PubMed: [7220891](https://pubmed.ncbi.nlm.nih.gov/7220891/)].
- Durr-e-Sabih, Sabih Z, Khan AN; Durr-e-Sabih. "Congealed waterlily" sign: a new sonographic sign of liver hydatid cyst. *J Clin Ultrasound*. 1996;**24**(6):297-303. [PubMed: [8792269](https://pubmed.ncbi.nlm.nih.gov/8792269/)].
- Kumar A, Kumar A, Gaurav K, Chandra G, Tiwary AK, Bhagat S, et al. A rare case of isolated hydatid cyst of breast. *Int J Surg Case Rep*. 2015;**7C**:115-8. doi: [10.1016/j.ijscr.2014.10.093](https://doi.org/10.1016/j.ijscr.2014.10.093). [PubMed: [25582084](https://pubmed.ncbi.nlm.nih.gov/25582084/)].
- Fidan-Ozbilgin O, Pambuccian SE, Mehrotra S. Intraoperative Finding of Hepatic Hydatid Cyst with Fine Needle Aspiration: A Case Study with AFB and GMS Special Stains Highlighting the Echinococcal Hooks. *J Cytol Histol*. 2016;**7**(3). doi: [10.4172/2157-7099.1000422](https://doi.org/10.4172/2157-7099.1000422).
- Geramizadeh B, Boob R, Talei AR, Rasekhi A. Fine needle aspiration cytology in hydatid cyst of the breast. *Acta Cytol*. 2003;**47**(4):701-2. [PubMed: [12920772](https://pubmed.ncbi.nlm.nih.gov/12920772/)].
- Cancelo MJ, Martin M, Mendoza N. Preoperative diagnosis of a breast hydatid cyst using fine-needle aspiration cytology: a case report and review of the literature. *J Med Case Rep*. 2012;**6**:293. doi: [10.1186/1752-1947-6-293](https://doi.org/10.1186/1752-1947-6-293). [PubMed: [22973941](https://pubmed.ncbi.nlm.nih.gov/22973941/)].
- Ghosh N, Bharti JN, Kaushal S, Jain S, Jain R. Isolated hydatid disease of the breast: fine-needle aspiration cytologic diagnosis in a clinically unsuspected case. *Breast J*. 2013;**19**(6):668-9. doi: [10.1111/tbj.12189](https://doi.org/10.1111/tbj.12189). [PubMed: [24112357](https://pubmed.ncbi.nlm.nih.gov/24112357/)].