



# Case Report of Successful Treatment of a Huge Gastric Bezoar by Electrohydraulic Lithotripsy, a Practiced Instrument in a New Fashion

Fardad Ejtehad, <sup>1,2</sup> Amir Anushiravani, <sup>2,\*</sup> Ehsan Zare, <sup>2</sup> Mohammad Reza Pashaei, <sup>3</sup> and Maryam Moini <sup>2,4</sup>

<sup>1</sup>Therapeutic Endoscopy and Advanced ERCP Ward, Namazi Hospital, Gastroenterology and Hepatology Section, Internal Medicine Department, School of Medicine, Shiraz University of Medical Sciences, Shiraz, Iran

<sup>2</sup>Gastroenterohepatology Research Center, School of Medicine, Shiraz University of Medical Sciences, Shiraz, Iran

<sup>3</sup>Department of Gastroenterology, Urmia University of Medical Sciences, Urmia, Iran

<sup>4</sup>Department of Internal Medicine, Gastroenterology and Hepatology Section, School of Medicine, Shiraz University of Medical Sciences, Shiraz, Iran

\*Corresponding author: Amir Anushiravani, Gastroenterohepatology Research Center, School of medicine, Shiraz University of Medical Sciences, Shiraz, Iran. Tel: +98-9173160616, E-mail: amiranush23@yahoo.com

Received 2017 October 01; Revised 2017 December 28; Accepted 2018 February 15.

## Abstract

**Introduction:** Gastric bezoars are formed by accumulation of non - digestible material in the stomach. They are found mostly in patients with delayed gastric emptying or special psychiatric diseases. Therapeutic options are medical dissolution therapy and endoscopic techniques. Surgery options are kept for refractory or emergency cases.

**Case Presentation:** We report 2 cases of successful non surgery, endoscopic treatment of huge gastric bezoars, which were refractory to medical dissolution therapy and conventional endoscopic techniques such as bezoar fragmentation by polypectomy snare, Basket, Argon Plasma Coagulation device, and different types of foreign body retrieval forceps. In June 2015 and September 2017 in the Namazi hospital (Shiraz University of Medical Sciences, Iran) bezoars fragmentation were conducted successfully by electrohydraulic lithotripsy catheter (Nortech Aoutolith and copy, Northgate technologies, INC.) under direct visualization during the endoscopy. This instrument is primarily designed to crush urinary tract and bile ducts stones avoiding open surgery. Taking the advantages of its capabilities, we used electrohydraulic lithotripsy catheter for huge gastric bezoar fragmentation.

**Conclusions:** In the endoscopic treatment refractory gastric bezoars, electrohydraulic lithotripsy can be used as an excellent alternative option to surgery. This technique is safe, feasible, and uncomplicated without any need for surgery.

**Keywords:** Bezoar, Foreign Body, Lithotripsy

## 1. Introduction

Bezoars are formed by the accumulation of non - digestible material in the GI tract and stomach is the most common site of bezoar formation (1). The word "Bezoar" seems to originate from the Persian word "Padzahr" or the Arabian word "Badzahr", which means antidote (2) since animal bezoars were used in traditional medicine (3). Gastric bezoar is a rare disease with an incidence rate of 0.7% to 0.4% among patients who had upper gastrointestinal endoscopy (4) although bezoars may form in the normal and healthy individuals, the major risk factors include gastric motility disorders, diabetic gastropathy, altered GI anatomy by previous surgery and psychiatric diseases (5). Bezoars are classified to 5 major subtypes according to their constituents. Phytobezoars are formed by seeds, skin, fibers, filaments of fruits and vegetables, as well as other indigestible components of the plants and vegetables. Ac-

cumulation of some medications such as stool bulking agents or slow releasing drugs may form Pharmacobezoars. Trichobezoars usually consist of patient's own hair in a setting of psychiatric disease called "trichotillomania" and "trichophagia". The hair bowel may be extended to the duodenum and causes Rapunzel syndrome (6) almost exclusively in young girls. Lactobezoars consist of undigested milk compound and some mucous material. The condition is rare and reported in milk powder fed infants (1). Gastric bezoars symptoms include, abdominal distention, abdominal pain, nausea and vomiting, evidence of gastric outlet obstruction, gastric ulcer, upper GI bleeding, and perforation (1, 5, 7). Treatment options include medical dissolution therapy, either alone or in combination with endoscopic techniques, and surgery.

Different types of endoscopic instruments are used for bezoar fragmentation. Polypectomy snares, baskets, Ar-

gon plasma coagulation system, various type of forceps, bezoaratom (1), and direct injection of Coca - Cola® to the bezoar are used for this purpose. Various types of solutions such as Coca - Cola®, Pepsi - Cola® (8), Cellulase, and Papain (1) are reported to be successful in the medical therapy of the bezoars, however, Coca - Cola® is the first choice of medical treatment of the bezoars. Surgery options, laparotomy or laparoscopy (9), are usually kept for the unresponsive cases or emergency conditions such as perforation and obstruction.

## 2. Case Presentation

### 2.1. Case 1

In June 2015, a 35 - year - old male patient with no history of surgery or pre - existing gastric disease had complaint of early satiety and fullness, endoscopy revealed huge gastric phytobezoar extending from the proximal part of the body to the antrum (Figure 1A), several attempts for dissolution therapy with kiwi fruit juice and Coca - Cola® ingestion followed by endoscopic techniques such as using forceps, snare, and direct injection of Coca - Cola® were unsuccessful. The bezoar was too firm in consistency to be injected in its core and too large to be fragmented by the snare. The patient refused the surgery option and was referred to Namazi hospital endoscopy center in Shiraz University of Medical Sciences in Iran for counselling. Due to decapitating symptoms, we decided to try electrohydraulic lithotripsy (Nortech Aoutolith®, Northgate technologies, INC.), which has been designed for biliary lithotripsy by Spyglass SpyGlass Direct Visualization System (Boston Scientific, Natick, Massachusetts, USA). Under moderate conscious sedation an endoscopy was done by Q190 (Olympus Co., Ltd., Tokyo, Japan) gastroscope. EHL (electrohydraulic lithotripsy) probe was passed through a needle knife catheter and then the needle knife catheter was passed through the working channel of the scope toward the stomach, the EHL device power, shot, and frequency were initially set on 20%, 5 per foot - pedal depression, and 15 per second, respectively. Power on demand was gradually increased. We kept a safe distance from the stomach wall to avoid collateral damage and to decrease the risk of gastric wall injury or perforation. The sparks of the EHL catheter were concentrated on the dome of the bezoar (Figure 1B). We continued to gimlet the bezoar until a hole was made in the bezoar (Figure 1C) large and deep enough to split it into 2 fragments. The endoscopy was repeated every two weeks for three more sessions and the small remaining fragments of the bezoar were crushed by the snare. Follow up endoscopy two months later revealed no bezoar and the patient had no complaint in the next year.

### 2.2. Case 2

In September 2017, an 18 - year - old man was referred to our center with similar complaints as the first case. He had no history of previous surgery, any medical disease or psychiatric problem. The patient had large gastric bezoars which was refractory to conventional treatment and endoscopic therapies. The bezoar size was larger than to be entrapped and fragmented by snare. According to our experience with the first case, Bezoar fragmentation was done by the same technique and devices with successful result and complete achievement in 3 separate endoscopy sections with no complication (Figure 2). Follow up endoscopy revealed no bezoar remnant and the patient do not have any complaint in OPD visits.

Table 1 demonstrates demographic and basic clinical data of both patients.

## 3. Discussion

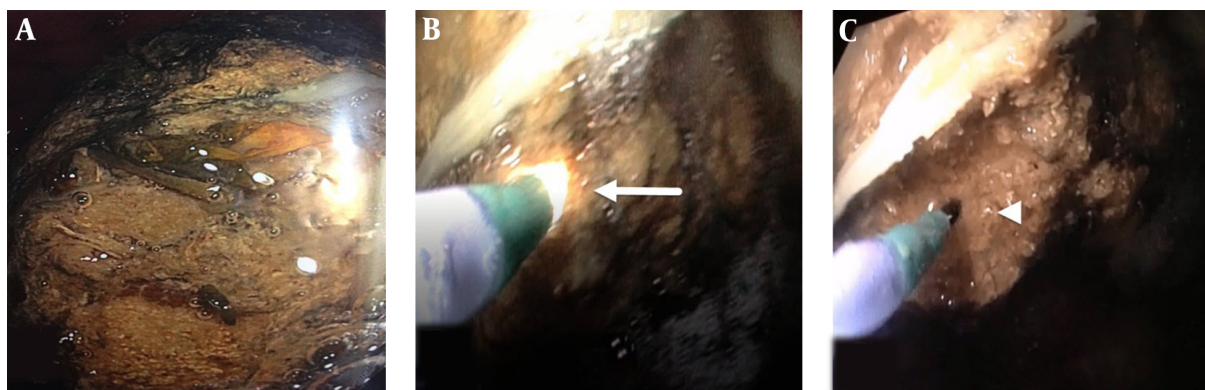
Gastric bezoars are divided to five subtypes; phytobezoars, trichobezoar (hairballs), Pharmacobezoars, lactobezoar, and miscellaneous type (1, 10). Phytobezoars are found mostly in the patients with prior gastric surgery, vagotomy, or in the patient with delayed emptying time of the stomach. Treatment options are dissolution by Coca - Cola® (11), endoscopic techniques, and surgery.

Different endoscopic instruments and techniques are used for fragmentation and retrieval of the gastric bezoars. Bezoar fragmentation can be performed by basket, polypectomy snare, Argon Plasma Coagulation devices, and different types of biopsy forceps (1). Refractory or emergency cases could be treated by surgery.

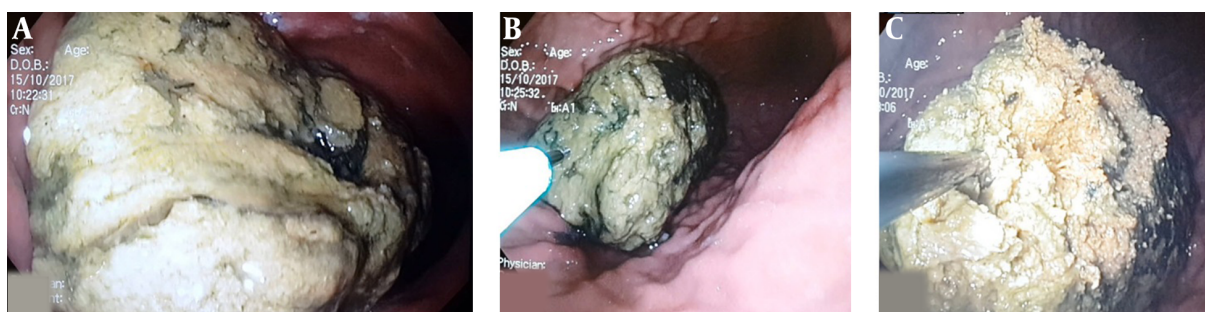
There are a few reports for application of electrohydraulic lithotripsy in the treatment of gastric bezoars. Electrohydraulic lithotripsy, which is a well - known technique for fragmentation of urinary system, has recently been reintroduced with Spyglass SpyGlass Direct Visualization System (Boston Scientific, Natick, Massachusetts, USA) for lithotripsy of the biliary stones during ERCP. In our cases we took advantage of “Through the scope” ability of the electrohydraulic lithotripsy catheter for fragmentation of a huge gastric bezoar in which treatment by conventional modalities was unsuccessful.

### 3.1. Conclusion

To our knowledge only a few cases of gastric fragmentation by electrohydraulic lithotripsy have been reported in the literature to date (10, 12-14). Our cases are unique in successful treatment of extremely large size gastric bezoar by using the “Through the scope” property of electrohydraulic lithotripsy catheter. Excellent results show



**Figure 1.** Shows Different Steps of Huge Gastric Bezoar Fragmentation by Electrohydraulic Lithotripsy. A: The Dome of the Huge Gastric Bezoar in the Proximal Part of the Body. B: The Spark of the Ehl (Arrow). C: The Initial Effect of the Ehl on the Bezoar (Arrow Head)



**Figure 2.** Demonstrates Fragmentation Steps of Huge Gastric Bezoar in the Second Case. A: The Proximal Part of the Huge Gastric Bezoar Which is Located near the Fundus. B: The Catheter of Ehl Which Was Passed Through a Needle Knife Catheter. C: Initial Fragmentation at the Dome of Bezoar

**Table 1.** Demographic and Clinical Data of Patients

	Age	Gender	Height (cm)	Weight (kg)	Blood Pressure (mmHg)	Previous Abdominal Surgery	History of Medical Disease	History of Psychiatric Disease	Known Gastric Motility Disease	Gastric Outlet Pathology
Case 1	35	Male	170	70	130/80	No	No	No	No	No
Case 2	18	Male	168	60	120/75	No	No	No	No	No

that this technique is very helpful in gastric bezoar fragmentation, especially when the bezoar size is large, other therapeutic options failed, and the technique could prevent surgery. In addition, we emphasize the value of this technique, which until now, has been given little attention. Although this technique has no complication in our patients, more patients are needed to identify any possible complications of this technique.

## References

- Iwamuro M, Okada H, Matsueda K, Inaba T, Kusumoto C, Imagawa A, et al. Review of the diagnosis and management of gastrointestinal bezoars. *World J Gastrointest Endosc.* 2015;7(4):336-45. doi: [10.4253/wjge.v7.i4.336](https://doi.org/10.4253/wjge.v7.i4.336). [PubMed: 25901212].
- Rabie ME, Arishi AR, Khan A, Ageely H, Seif El-Nasr GA, Fagihi M. Rapunzel syndrome: the unsuspected culprit. *World J Gastroenterol.* 2008;14(7):1141-3. [PubMed: 18286701].
- Williams RS. The fascinating history of bezoars. *Med J Aust.* 1986;145(11-12):613-4. [PubMed: 3540541].
- Akbulut S, Deger KC, Duman M, Yol S. Gastric bezoars. *Prz Gastroenterol.* 2016;11(1):60-1. doi: [10.5114/pg.2015.55188](https://doi.org/10.5114/pg.2015.55188). [PubMed: 27110315].
- Eng K, Kay M. Gastrointestinal bezoars: history and current treatment paradigms. *Gastroenterol Hepatol (N Y).* 2012;8(11):776-8. [PubMed: 24672418].
- Wang Z, Cao F, Liu D, Fang Y, Li F. The diagnosis and treatment of Rapunzel syndrome. *Acta Radiol Open.* 2016;5(11):2.0584601156277E+15. doi: [10.1177/20584601156277660](https://doi.org/10.1177/20584601156277660). [PubMed: 27900201].
- Katsinelos P, Pilpilidis I, Chatzimavroudis G, Katsinelos T, Lazaraki G, Fasoulas K, et al. Huge gastric bezoar caused by honeycomb, an unusual complication of health faddism: a case report. *Cases J.* 2009;2:7077. doi: [10.1186/1757-1626-2-7077](https://doi.org/10.1186/1757-1626-2-7077). [PubMed: 19829904].
- Iwamuro M, Yunoki N, Tomoda J, Nakamura K, Okada H, Yamamoto K. Gastric Bezoar Treatment by Endoscopic Fragmentation in Combination with Pepsi-Cola(R) Administration. *Am J Case Rep.* 2015;16:445-8. doi: [10.12659/AJCR.893786](https://doi.org/10.12659/AJCR.893786). [PubMed: 26164451].

9. Sharma D, Srivastava M, Babu R, Anand R, Rohtagi A, Thomas S. Laparoscopic treatment of gastric bezoar. *JSLs*. 2010;**14**(2):263-7. doi: [10.4293/108680810X12785289144566](https://doi.org/10.4293/108680810X12785289144566). [PubMed: [20932381](https://pubmed.ncbi.nlm.nih.gov/20932381/)].
10. Kuo JY, Mo LR, Tsai CC, Chou CY, Lin RC, Chang KK. Nonoperative treatment of gastric bezoars using electrohydraulic lithotripsy. *Endoscopy*. 1999;**31**(5):386-8. doi: [10.1055/s-1999-24](https://doi.org/10.1055/s-1999-24). [PubMed: [10433049](https://pubmed.ncbi.nlm.nih.gov/10433049/)].
11. Ladas SD, Kamberoglou D, Karamanolis G, Vlachogiannakos J, Zouboulis-Vafiadis I. Systematic review: Coca-Cola can effectively dissolve gastric phytobezoars as a first-line treatment. *Aliment Pharmacol Ther*. 2013;**37**(2):169-73. doi: [10.1111/apt.12141](https://doi.org/10.1111/apt.12141). [PubMed: [23252775](https://pubmed.ncbi.nlm.nih.gov/23252775/)].
12. Iwamuro M, Tanaka S, Shiode J, Imagawa A, Mizuno M, Fujiki S, et al. Clinical characteristics and treatment outcomes of nineteen Japanese patients with gastrointestinal bezoars. *Intern Med*. 2014;**53**(11):1099-105. [PubMed: [24881731](https://pubmed.ncbi.nlm.nih.gov/24881731/)].
13. Kuo JY, Mo LR, Tsai CC, Yueh SK, Lin RC, Hwang MH. Endoscopic fragmentation of gastric phytobezoar by electrohydraulic lithotripsy. *Gastrointest Endosc*. 1993;**39**(5):706-8. [PubMed: [8224699](https://pubmed.ncbi.nlm.nih.gov/8224699/)].
14. Muguruma N, Okamura S, Okahisa T, Yasuda M, Hayashi S, Shibata H, et al. Electrohydraulic lithotripsy treatment for persimmon bezoars. *Endoscopy*. 1998;**30**(5).S60. [PubMed: [9693910](https://pubmed.ncbi.nlm.nih.gov/9693910/)].