



The Correlation Between Hip Morphology and Hip Osteoarthritis: A Cross-Sectional Study

Mohammad Kazem Emami Meybodi¹, Hamid Reza Rasouli¹, Mohammad Ghafouri², Shabnam Akhoundzadeh Bafghi¹ and Mojtaba Ghafouri^{1,*}

¹Trauma Research Center, Baqiyatallah University of Medical Sciences, Tehran, Iran

²Students, Scientific Research Center, Tehran University of Medical Sciences, Tehran, Iran

*Corresponding author: Trauma Research Center, Baqiyatallah University of Medical Sciences, Tehran, Iran. Tel/Fax: +98-3538201732, E-mail: ghafouri_mojtaba@yahoo.com

Received 2017 August 19; Revised 2017 December 05; Accepted 2017 December 21.

Abstract

Background: Osteoarthritis (OA) is a highly prevalent chronic degenerative joint disease with different risk factors, which need to be investigated in order to perform more appropriate interventions in earlier phases of Osteoarthritis.

Objectives: Therefore, the aim of this study was to determine the correlation between hip morphology and hip Osteoarthritis.

Methods: This cross-sectional study was conducted on patients aged 15 to 60 years old with hip problems, diagnosed with hip Osteoarthritis, compared with healthy individuals as the control group. Then radiographic parameters, such as alpha angle, acetabular angle of sharp (AA), lateral center-edge angle (LCEA), femoral neck-shaft angle (FNA), coxa profunda, acetabular protrusio, crossover sign, posterior wall sign, and the ischial sign were measured by pelvic (AP) X-ray, using PACS systems in both groups.

Results: This study found that alpha angle and AA were significantly greater in OA patients as compared to healthy individuals ($P < 0.001$). Furthermore, LCEA was significantly greater in the Osteoarthritis group on the left side as compared to the control group (38.93 ± 8.43 versus 36.81 ± 4.74 , $P = 0.042$) yet LCEA on the right side and total amount were not different between the two groups ($P > 0.05$). By grouping studied angles, it was found that the frequency of alpha angle $> 55^\circ$, AA $> 38^\circ$, and LCEA $> 40^\circ$ were significantly higher in the OA group as compared to the control group ($P < 0.05$). Furthermore, the researchers observed that the frequency of acetabular protrusio ($P = 0.013$) and posterior wall sign were significantly higher in the OA group as compared to healthy individuals ($P < 0.05$).

Conclusions: The current results showed that the higher Body Mass Index (BMI), greater alpha and acetabular angles, sharp, lateral center-edge angle center-edge angle, the higher rate of a posterior wall sign, and acetabular protrusio increased the risk of OA, which support that these structural changes are major contributors to OA development.

Keywords: Degenerative Disease, Hip, Joint, Morphology, Osteoarthritis, Radiography

1. Background

Osteoarthritis (OA) is a highly prevalent chronic degenerative joint disease, especially in the elderly age group (1). Hip and knee are the most common joints affected by OA degenerative changes, which limit daily living activities, such as walking, transposition of obstacles, home care, and work activities (2). The cause of hip OA remains unclear, and several risk factors have been introduced, especially in the elderly age group, such as aging, obesity, overuse, male gender, and joint trauma (2, 3). Other risk factors have also been introduced, especially in young adult patients, such as developmental dysplasia of the hip (DDH), Perthes disease, and slipped capital femoral epiphysis (SCFE) (4). There is a growing body of evidence supporting the correlation between hip OA and morphologic features, including femoral head-tilt, acetabular over coverage, reduced

acetabular, femoral anteversion, pelvic incidence (PI), and femoral head asphericity (5-8). Therefore, the hip morphologic risk factors are a clue for prevention and early diagnosis of OA, especially in those with the idiopathic type (9-11).

Abnormal hip radiographic features have been investigated in various geographic populations, including Japan (12), China (13), Denmark (14), African Americans (15), Netherlands (16), and the United Kingdom (17), and in specific athletic populations (15). A recent study reported higher prevalence of abnormal hip radiographic measures and OA among Caucasians compared to Asian females (13). Thus, it seems that the prevalence of hip morphology abnormalities is influenced by race. However, there is no evidence of variations in the hip morphology among Iranian population. Additionally, very few studies have reported on various radiographic characteristics of OA for comparison. Therefore, this study for the first time aimed

at evaluating the correlation between different hip radiologic measures and OA among Iranians.

2. Methods

2.1. Patients

A total of 146 patients (50 cases and 96 controls) aged 15 to 60 years, who referred to an orthopedic clinic of Baqiyatallah Hospital, Tehran, Iran, were included in this cross-sectional study, between March 2016 to May 2017. Informed consent was obtained from all participants. The study received ethics approval from the Ethics committee of Baqiyatallah University of Medical Sciences (IR.BMSU.REC.1394.192).

A recent pilot study showed that the incidence of an alpha angle of more than 55 degrees was 64% and 17% among OA and control groups, respectively. Considering these results, and the estimated missing data, the sample size for 99.5% power at 5% level of significance was 50, using the below formula. To increase the power, given the expected prevalence of exposure among the controls, a case: control ratio of 1:2 was considered. Accordingly, 95 patients with OA and 98 healthy individuals, who underwent pelvic x-ray, were randomly selected. For this purpose, all the patients' recording codes were collected, and finally, codes of patients were randomly selected.

$$n = 2 \frac{\left(z_{1-\frac{\alpha}{2}} + z_{1-\beta}\right)^2 \overline{pq}}{(p_1 - p_2)^2} \quad (1)$$

Patients with a hip joint problem (pain, asymmetry, and restriction of movement) were evaluated as the case group. However, those with a history of hip trauma, hip infectious arthritis, rheumatoid arthritis, neuromuscular disorders, fracture or dislocation of lower extremities, hip or lower extremities surgery, total hip arthroplasty, and advanced hip degenerative changes (tonnis grade > 2) were excluded from the cases. Participants with no complaints of hip pain were included as controls. The patients with abnormal radiography, such as any grade of hip degenerative changes, osteonecrosis of the femoral head, and error in tilt and rotation criteria in pictures, were excluded from the control group. The pelvic rotation was evaluated by checking the alignment of coccyx and symphysis pubis. Pelvic tilt was evaluated by measuring the height of the sacrococcygeal joint above the symphysis pubis (9). This study also excluded all the participants with incomplete data or poor quality of radiographs. The study flowchart is shown in Figure 1.

All the radiographs were assessed by an experienced orthopedic surgeon (interobserver k 0.864 and intraobserver 0.806), who was blinded to the study groups, using

the horizon picture archiving and communications system (PACS) (Marco Dicom Viewer, version: 7.16.1.381). The system was calibrated to minimize the chance of instrumental errors.

2.2. Radiographic Variables

The researchers selected eight key morphology parameters related to cam deformity (alpha angle), acetabular coverage (LCEA, acetabular protrusio, acetabular index, and coxa profunda), acetabular retroversion (posterior wall sign, crossover sign, and ischial spine sign), and femoral anteversion (FNA) (Table 1).

2.3. Data Analysis

Data were analyzed and reported only for patients with completed information using IBM SPSS Statistics for Windows, version 22.0 (IBM Corp., Armonk, N.Y., USA). Chi-square test was used to compare qualitative variables between groups. Kolmogorov-Smirnov test was used in order to evaluate normal distribution of all quantitative studied parameters. Student's t-test and paired t-test were used for variables with normal distribution; Mann-Whitney U test and Wilcoxon tests were used for variables without normal distribution. Two-tailed P values of less than 0.05 were considered significant.

3. Results

All the quantitative data did not have normal distribution with exception of the left CEA. The median and interquartile range (IQR) of age (49.5 and 17 years), height (165 and 15 cm), weight (71.5 and 15.5 kg), BMI (25.36 and 6.03), left Acetabular Angle of sharp (AA) (36.2° and 3.45°), right AA (36.25° and 3.05°), left FNA (130° and 5.78°), right FNA (130.35° and 5.3°), left alpha angle (49.45° and 10.1°), right alpha angle (50.1° and 10.15°), left CEA (36.7° and 8.05°), and right CEA (36.8° and 7.77°) were measured.

The results of the current study showed that demographic feature in terms of gender (P = 0.787) was similar in both OA and control groups. Furthermore, BMI was significantly higher in the OA group (P < 0.001) (Table 2).

Additionally, alpha angle and AA on the right and left side and in total amount were significantly greater in OA patients, as compared to healthy individuals (P < 0.001). However, lateral central-edge angle (LCEA) was significantly greater in the OA group on the left side as compared to the control group (P = 0.042) yet LCEA on the right side and total amount were not different between the two groups (P > 0.05). Moreover, the current study did not observe significant differences in FNA on both right and left side and in the total amount (P > 0.05) (Table 3).

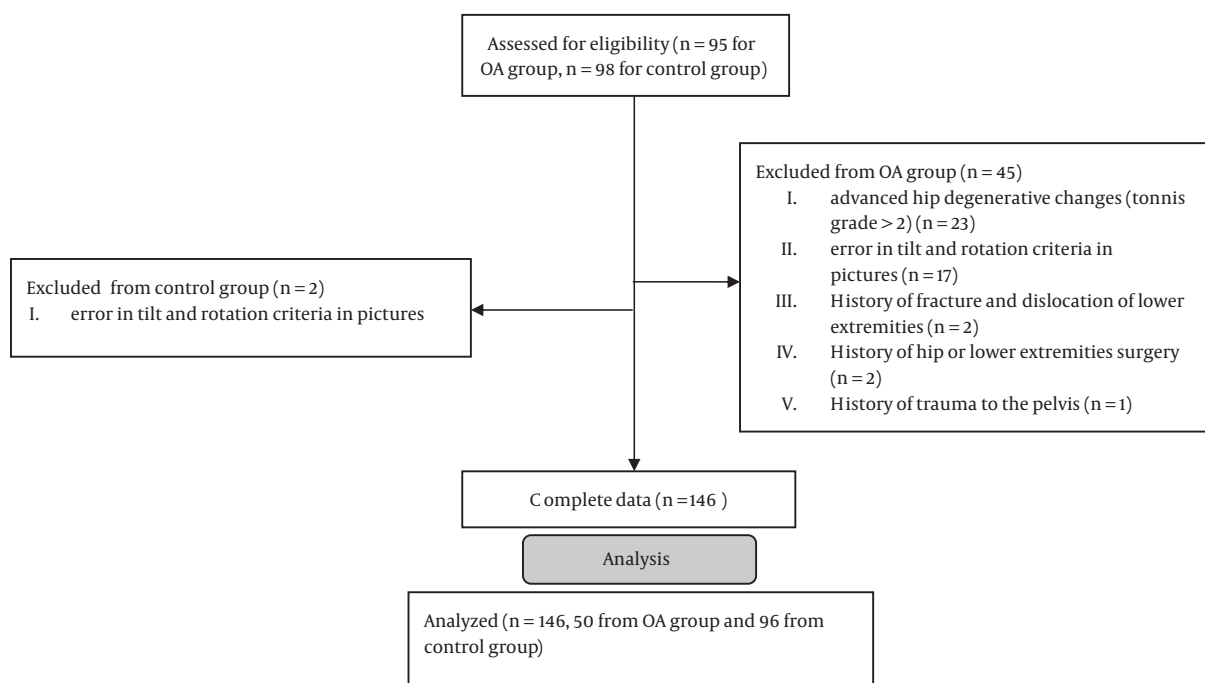


Figure 1. Study flowchart

Table 1. Morphologic Parameters in Hip Radiography and Their Association with various Hip Pathologies

Morphologic Parameter	Definition	Normal	Abnormal
Alpha (α) angle	The angle between the femoral neck axis and the line connecting the head center with the point of beginning sphericity of the head-neck contour.	< 15°	> 50° (10) or 55° (11) is associated with CAM type of impingement
Acetabular angle of sharp	Angle formed by a horizontal line and a line through the caudal tip of the teardrop and the lateral edge of the acetabulum (18).	33° - 38°	> 47° is associated with acetabular dysplasia (4) 39° to 46° is indeterminate
Lateral center-edge angle (LCEA)	Angle between a vertical line and the line connecting the femoral head center with the lateral edge of the acetabulum (10).		if < 20° then dysplasia if > 40° then acetabular over coverage, pincer type of impingement (19)
Femoral neck-shaft (FNA) angle	Angle formed by axis of femoral shaft and line drawn along axis of femoral neck passing through the center of head of femur (20).	125° - 135°	if < 125° then coxa varus deformity, if > 135° then coxa valgus deformity (20)
Coxa profunda	The deep acetabular fossa being medial to the ischiotibial line (10).		Non-specific, Pincer type of impingement (10)
Coxa protrusion	Intrapelvic displacement of the acetabulum and femoral head, so that the femoral head projects medial to the ischiotibial line (10).		Pincer type of impingement (10)
Crossover sign	Posterior margin of acetabulum crosses the anterior margin and the inferior part of posterior margin lies medial to the anterior margin producing a figure of 8 pattern.		Acetabular retroversion
Ischial spine sign	Prominent ischial spine projecting medial to the pelvic brim.		Acetabular retroversion (21)
Posterior wall sign	Posterior margin of acetabulum lies medial to the center of femoral head.		Acetabular retroversion, Pincer type of impingement (10)

By grouping the studied angles, it was found that the frequency of alpha angle > 55°, AA > 38°, and LCEA > 40°

Table 2. Demographic Variables in Both Osteoarthritis and Control Groups

Variables	Group		P Value
	OA (N = 50)	Control (N = 96)	
Sex, male, No. (%)	22 (44)	40 (41.7)	0.787
Height, cm	165.92 ± 8.11	168.32 ± 8.91	0.192
Weight, kg	78.12 ± 10.8	69.33 ± 9.89	< 0.001
BMI, kg/m ²	28.49 ± 4.24	24.47 ± 3.08	< 0.001

Abbreviation: BMI, Body Mass Index.

Table 3. Radiographic Variables in Both Osteoarthritis and Control Groups

Variables	Group		P Value
	OA (N = 50)	Control (N = 96)	
Alpha angle, degree			
Right side	58.43 ± 12.09	51.26 ± 6.41	< 0.001
Left side	56.33 ± 9.62	50.78 ± 6.37	< 0.001
Total	57.38 ± 10.0	51.02 ± 6.30	< 0.001
AA, degree			
Right side	38.73 ± 6.91	35.92 ± 2.51	< 0.001
Left side	38.49 ± 5.17	35.74 ± 2.52	0.006
Total	38.61 ± 5.41	35.83 ± 2.36	< 0.001
LCEA, degree			
Right side	38.96 ± 10.19	37.08 ± 4.33	0.103
Left side	38.93 ± 8.43	36.81 ± 4.74	0.042
Total	38.94 ± 8.65	36.94 ± 4.44	0.054
FNA, degree			
Right side	130.97 ± 3.95	130.08 ± 4.5	0.047
Left side	130.84 ± 4.80	129.93 ± 4.5	0.068
Total	130.9 ± 3.75	130.01 ± 4.23	0.188

Abbreviations: AA, Acetabular Angle of Sharp; FNA, Femoral Neck-Shaft Angle; LCEA, Lateral Center-Edge Angle.

on the right, left, and both sides (right and left side) were significantly more in the OA group as compared to the control group ($P < 0.05$) (Table 4).

Furthermore, four (4%) pelvic with acetabular protrusion were observed in the OA group, while no case was observed in the control group ($P = 0.013$). Moreover, the frequency of posterior wall sign was significantly higher in the OA group as compared to healthy individuals on the right ($P = 0.005$), left ($P < 0.001$), and both sides ($P < 0.001$). However, significant differences were not observed in the rate of coxa profunda, crossover sign, and ischial sign in both groups ($P > 0.05$) (Table 5).

Table 4. Radiographic Variables in Both Osteoarthritis and Control Groups^a

Variables	Group		P Value
	OA (N = 50)	Control (N = 96)	
Alpha angle > 55°			
Right side	31 (62)	17 (17.7)	< 0.001
Left side	33 (66)	17 (17.7)	< 0.001
Both sides	64 (64)	34 (17.7)	< 0.001
AA > 38°			
Right side	23 (46)	12 (12.5)	< 0.001
Left side	22 (44)	12 (12.5)	< 0.001
Both sides	45 (45)	24 (12.5)	< 0.001
LCEA > 40°			
Right side	25 (50)	21 (21.9)	0.001
Left side	24 (48)	21 (21.9)	0.002
Both sides	49 (49)	42 (21.9)	< 0.001
FNA > 135°			
Right side	5 (10)	15 (15.6)	0.450
Left side	4 (8)	10 (10.4)	0.772
Both sides	9 (9)	25 (13)	0.343
FNA < 125°			
Right side	0 (0)	8 (8.3)	0.051
Left side	1 (2)	9 (9.4)	0.165
Both sides	1 (1)	17 (8.9)	0.008

Abbreviations: AA, Acetabular Angle of Sharp; FNA, Femoral Neck Shaft Angle; LCEA, Lateral Center-Edge Angle.

^aValues are expressed as No. (%).

4. Discussion

The current results showed high BMI as a risk factor for hip OA. The results also showed that an alpha angle of > 55° and AA > 38° were significantly greater among the OA group. Moreover, posterior wall sign and acetabular protrusion were observed more frequently in OA patients. Taken together, the current findings are in agreement with prior work, done in various geographic regions, showing that cam deformity and acetabular over coverage are more frequent in OA patients (12, 13, 15-17, 22-24). To date, barely no studies with OA outcomes have reported on all of these measures, specifically among the Iranian population for comparison, while, the prevalence of hip radiographic features may be influenced by race (13).

Although, the current results showed that the posterior wall sign was associated with OA, no statistically significant association was seen between other radiographic signs of acetabular retroversion (crossover and ischial spine signs) and OA. The posterior wall sign literally rep-

Table 5. Radiographic Variables in Both Osteoarthritis and Control Groups^a

Variables	Group		P Value
	OA (N = 50)	Control (N = 96)	
Coxa profunda			
Right side	23 (46)	43 (44.8)	1
Left side	24 (48)	45 (46.9)	1
Both sides	47 (47)	88 (45.8)	0.902
Acetabular protrusio			
Right side	2 (4)	0 (0)	0.116
Left side	2 (4)	0 (0)	0.116
Both sides	4 (4)	0 (0)	0.013
Cross over sign			
Right side	18 (36)	33 (34.4)	0.857
Left side	23 (46)	30 (31.3)	0.103
Both sides	41 (41)	63 (32.8)	0.198
Posterior wall sign			
Right side	21 (42)	18 (18.8)	0.005
Left side	25 (50)	18 (18.8)	< 0.001
Both sides	46 (46)	36 (18.8)	< 0.001
Ischial sign			
Right side	15 (30)	41 (42.7)	0.154
Left side	21 (42)	38 (39.6)	0.859
Both sides	36 (36)	79 (41.1)	0.449

^aValues are expressed as No. (%).

resented insufficient posterior femoral head coverage and may be positive in global insufficient coverage, even in absence of retroversion (25). In addition, according to Werner (26), the combined presence of all three radiographic signs is an indicator of acetabular retroversion. Thus, the contribution of this measure with OA in this study is mostly attributed to the decrease in global insufficient coverage of femoral head.

Concurrent with the current results, the CHECK study (22), a nationwide study in the Netherlands, or in the Chingford 1000 women study (24), a population-based study of females in the UK demonstrated that cam morphologies are predictive of OA. Additionally, Agricola et al. (22), Ecker et al. (27), and Scheidt et al. (28) demonstrated that individuals with greater alpha angles representing the cam deformity, are at risk of developing OA.

In accordance with the current findings, analyses of a cohort study performed by Nelson et al. (15) confirmed the association of greater alpha angles and acetabular over coverage signs (protrusio acetabula yet not coxa profunda), with OA regardless of gender. Nicholls et al. (17)

also revealed that alpha angle and acetabular index predicted the risk of end-stage osteoarthritis of the hip while coxa profunda was more commonly present in the controls. The researchers also did not found any relationship among coxa profunda and OA. Additionally, coxa profunda is known as a non-specific radiographic finding in hip disorders, which is neither necessary nor sufficient to support a diagnosis of pincer-type femoroacetabular impingement (29).

Furthermore, the present findings showed that FNA was not different among OA patients ($130.9 \pm 3.75^\circ$) and the control group ($130.01 \pm 4.23^\circ$). The current results were similar to previous investigations, which showed the femoral neck-shaft angle is about 128° in normal hips (1) and 129° in patients with OA (30).

In addition, pincer (LCEA > 40° or acetabular protrusio) morphology measures were not related to the OA in the CHECK study (16) or in the Chingford 1000 women study (24). The CHECK study also claimed that pincer morphology has protective effects against OA, in contrast to the current results and some recent investigations, in which protrusio acetabula, consistent with over coverage (18), was associated with hip OA (15). Additionally, the present findings revealed that LCEA was not different between the two groups, regardless of sidedness, while it was significantly greater in the OA group on the left side.

Sidedness has been infrequently assessed in hip OA and the findings are controversial in this regard. Similar to Bouyer et al.'s findings (31), the current results showed no significant difference by side with respect to the morphological parameters with the exception of LCEA. However, previous reports have noticed slightly smaller CEA (32) and higher alpha angles (33) on the right compared with the left hip. Additionally, the frequency of hip OA and (34) total hip replacement (35) are more frequent in the right hip. These controversial findings, maybe explained by racial differences and thus interactions between side and the morphology variables should be more explored in other populations.

The strong points of this study are the reasonable sample size, highly reliable reader, using validated software, and assessing the hip X-rays using different radiographic variables. The samples were all collected from a general center with referrals from all over the country. Thus, this study provides the first estimates of various morphologic measures in the Iranian population. However, a community-based sample would be a better representative of the population, to which the findings could be generalized. The other limitation was the cross-sectional design, which cannot be suggestive of etiologic relationships.

4.1. Conclusions

The results of the current study among the Iranian population are representative of the association of higher BMI, cam deformity (increased alpha angle), and acetabular over coverage (acetabular protrusio yet not coxa profunda, increased LCEA, and acetabular index) with OA. These findings support that the mentioned structural changes would be the major contributors to OA development.

Acknowledgments

This study was financially supported by the trauma research center of Baqiyatallah Medical Sciences University, Tehran, center of Iran. The authors gratefully acknowledge the dedicated efforts of the investigators, the coordinators, the volunteer patients, who participated in this study, and the clinical research development units (CRDU) of Baqiyatallah Hospital.

Footnote

Conflict of Interests: The authors indicated that they had no conflicts of interest regarding the content of this article.

References

- Felson DT, Naimark A, Anderson J, Kazis L, Castelli W, Meenan RF. The prevalence of knee osteoarthritis in the elderly. The Framingham Osteoarthritis Study. *Arthritis Rheum.* 1987;**30**(8):914-8. doi: [10.1002/art.1780300811](https://doi.org/10.1002/art.1780300811). [PubMed: [3632732](https://pubmed.ncbi.nlm.nih.gov/3632732/)].
- Salvato KF, Santos JP, Pires-Oliveira DA, Costa VS, Molari M, Fernandes MT, et al. [Analysis of the influence of pharmacotherapy on the quality of life of seniors with osteoarthritis]. *Rev Bras Reumatol.* 2015;**55**(1):83-8. doi: [10.1016/j.rbr.2014.08.006](https://doi.org/10.1016/j.rbr.2014.08.006). [PubMed: [25476475](https://pubmed.ncbi.nlm.nih.gov/25476475/)].
- Loughlin J. The genetic epidemiology of human primary osteoarthritis: current status. *Expert Rev Mol Med.* 2005;**7**(9):1-12. doi: [10.1017/S1462399405009257](https://doi.org/10.1017/S1462399405009257). [PubMed: [15910695](https://pubmed.ncbi.nlm.nih.gov/15910695/)].
- Hoaglund FT, Steinbach LS. Primary osteoarthritis of the hip: etiology and epidemiology. *J Am Acad Orthop Surg.* 2001;**9**(5):320-7. doi: [10.5435/00124635-200109000-00005](https://doi.org/10.5435/00124635-200109000-00005). [PubMed: [11575911](https://pubmed.ncbi.nlm.nih.gov/11575911/)].
- Castaneda P, Ponce C, Villareal G, Vidal C. The natural history of osteoarthritis after a slipped capital femoral epiphysis/the pistol grip deformity. *J Pediatr Orthop.* 2013;**33** Suppl 1:S76-82. doi: [10.1097/BPO.0b013e318277174c](https://doi.org/10.1097/BPO.0b013e318277174c). [PubMed: [23764797](https://pubmed.ncbi.nlm.nih.gov/23764797/)].
- Tonnis D, Heinecke A. Acetabular and femoral anteversion: relationship with osteoarthritis of the hip. *J Bone Joint Surg Am.* 1999;**81**(12):1747-70. doi: [10.2106/00004623-199912000-00014](https://doi.org/10.2106/00004623-199912000-00014). [PubMed: [10608388](https://pubmed.ncbi.nlm.nih.gov/10608388/)].
- Sartoris DJ, Resnick D, Bielecki D, Gershuni D, Meyers M. Computed tomography with multiplanar reformation and three-dimensional image reconstruction in the preoperative evaluation of adult hip disease. *Int Orthop.* 1988;**12**(1):1-8. doi: [10.1007/BF00265734](https://doi.org/10.1007/BF00265734). [PubMed: [3372096](https://pubmed.ncbi.nlm.nih.gov/3372096/)].
- Yoshimoto H, Sato S, Masuda T, Kanno T, Shundo M, Hyakumachi T, et al. Spinopelvic alignment in patients with osteoarthrosis of the hip: a radiographic comparison to patients with low back pain. *Spine (Phila Pa 1976).* 2005;**30**(14):1650-7. doi: [10.1097/01.brs.0000169446.69758.fa](https://doi.org/10.1097/01.brs.0000169446.69758.fa). [PubMed: [16025036](https://pubmed.ncbi.nlm.nih.gov/16025036/)].
- Siebenrock KA, Kalbermatten DF, Ganz R. Effect of pelvic tilt on acetabular retroversion: a study of pelvis from cadavers. *Clin Orthop Relat Res.* 2003;**407**:241-8. [PubMed: [12567152](https://pubmed.ncbi.nlm.nih.gov/12567152/)].
- Tannast M, Siebenrock KA, Anderson SE. Femoroacetabular impingement: radiographic diagnosis-what the radiologist should know. *AJR Am J Roentgenol.* 2007;**188**(6):1540-52. doi: [10.2214/AJR.06.0921](https://doi.org/10.2214/AJR.06.0921). [PubMed: [17515374](https://pubmed.ncbi.nlm.nih.gov/17515374/)].
- Phillippon M, Dewing C, Briggs K, Steadman JR. Decreased femoral head-neck offset: a possible risk factor for ACL injury. *Knee Surg Sports Traumatol Arthrosc.* 2012;**20**(12):2585-9. doi: [10.1007/s00167-012-1881-1](https://doi.org/10.1007/s00167-012-1881-1). [PubMed: [22286743](https://pubmed.ncbi.nlm.nih.gov/22286743/)]. [PubMed Central: [PMC3505489](https://pubmed.ncbi.nlm.nih.gov/PMC3505489/)].
- Fukushima K, Uchiyama K, Takahira N, Moriya M, Yamamoto T, Itoman M, et al. Prevalence of radiographic findings of femoroacetabular impingement in the Japanese population. *J Orthop Surg Res.* 2014;**9**:25. doi: [10.1186/1749-799X-9-25](https://doi.org/10.1186/1749-799X-9-25). [PubMed: [24725368](https://pubmed.ncbi.nlm.nih.gov/24725368/)]. [PubMed Central: [PMC3990223](https://pubmed.ncbi.nlm.nih.gov/PMC3990223/)].
- Dudda M, Kim YJ, Zhang Y, Nevitt MC, Xu L, Niu J, et al. Morphologic differences between the hips of Chinese women and white women: could they account for the ethnic difference in the prevalence of hip osteoarthritis? *Arthritis Rheum.* 2011;**63**(10):2992-9. doi: [10.1002/art.30472](https://doi.org/10.1002/art.30472). [PubMed: [21647861](https://pubmed.ncbi.nlm.nih.gov/21647861/)]. [PubMed Central: [PMC3178680](https://pubmed.ncbi.nlm.nih.gov/PMC3178680/)].
- Gosvig KK, Jacobsen S, Sonne-Holm S, Palm H, Troelsen A. Prevalence of malformations of the hip joint and their relationship to sex, groin pain, and risk of osteoarthritis: a population-based survey. *J Bone Joint Surg Am.* 2010;**92**(5):1162-9. doi: [10.2106/JBJS.H.01674](https://doi.org/10.2106/JBJS.H.01674). [PubMed: [20439662](https://pubmed.ncbi.nlm.nih.gov/20439662/)].
- Nelson AE, Stiller JL, Shi XA, Leyland KM, Renner JB, Schwartz TA, et al. Measures of hip morphology are related to development of worsening radiographic hip osteoarthritis over 6 to 13 year follow-up: the Johnston County Osteoarthritis Project. *Osteoarthritis Cartilage.* 2016;**24**(3):443-50. doi: [10.1016/j.joca.2015.10.007](https://doi.org/10.1016/j.joca.2015.10.007). [PubMed: [26497609](https://pubmed.ncbi.nlm.nih.gov/26497609/)]. [PubMed Central: [PMC4761268](https://pubmed.ncbi.nlm.nih.gov/PMC4761268/)].
- Agricola R, Heijboer MP, Roze RH, Reijman M, Bierma-Zeinstra SM, Verhaar JA, et al. Pincer deformity does not lead to osteoarthritis of the hip whereas acetabular dysplasia does: acetabular coverage and development of osteoarthritis in a nationwide prospective cohort study (CHECK). *Osteoarthritis Cartilage.* 2013;**21**(10):1514-21. doi: [10.1016/j.joca.2013.07.004](https://doi.org/10.1016/j.joca.2013.07.004). [PubMed: [23850552](https://pubmed.ncbi.nlm.nih.gov/23850552/)].
- Nicholls AS, Kiran A, Pollard TC, Hart DJ, Arden CP, Spector T, et al. The association between hip morphology parameters and nineteen-year risk of end-stage osteoarthritis of the hip: a nested case-control study. *Arthritis Rheum.* 2011;**63**(11):3392-400. doi: [10.1002/art.30523](https://doi.org/10.1002/art.30523). [PubMed: [21739424](https://pubmed.ncbi.nlm.nih.gov/21739424/)]. [PubMed Central: [PMC3494291](https://pubmed.ncbi.nlm.nih.gov/PMC3494291/)].
- Tannast M, Hanke MS, Zheng G, Steppacher SD, Siebenrock KA. What are the radiographic reference values for acetabular under- and overcoverage? *Clin Orthop Relat Res.* 2015;**473**(4):1234-46. doi: [10.1007/s11999-014-4038-3](https://doi.org/10.1007/s11999-014-4038-3). [PubMed: [25384429](https://pubmed.ncbi.nlm.nih.gov/25384429/)]. [PubMed Central: [PMC4353515](https://pubmed.ncbi.nlm.nih.gov/PMC4353515/)].
- Monazzam S, Bomar JD, Cidambi K, Kruk P, Hosalkar H. Lateral center-edge angle on conventional radiography and computed tomography. *Clin Orthop Relat Res.* 2013;**471**(7):2233-7. doi: [10.1007/s11999-012-2651-6](https://doi.org/10.1007/s11999-012-2651-6). [PubMed: [23070664](https://pubmed.ncbi.nlm.nih.gov/23070664/)]. [PubMed Central: [PMC3676615](https://pubmed.ncbi.nlm.nih.gov/PMC3676615/)].
- Nardo L, Parimi N, Liu F, Lee S, Jungmann PM, Nevitt MC, et al. Femoroacetabular Impingement: Prevalent and Often Asymptomatic in Older Men: The Osteoporotic Fractures in Men Study. *Clin Orthop Relat Res.* 2015;**473**(8):2578-86. doi: [10.1007/s11999-015-4222-0](https://doi.org/10.1007/s11999-015-4222-0). [PubMed: [25736918](https://pubmed.ncbi.nlm.nih.gov/25736918/)]. [PubMed Central: [PMC4488192](https://pubmed.ncbi.nlm.nih.gov/PMC4488192/)].
- Deborah Pate D. The ischial spine: A radiographic sign for acetabular retroversion. *Dyn Chiropr.* 2011;**29**(20).
- Agricola R, Heijboer MP, Bierma-Zeinstra SM, Verhaar JA, Weinans H, Waarsing JH. Cam impingement causes osteoarthritis of the hip: a nationwide prospective cohort study (CHECK). *Ann Rheum Dis.* 2013;**72**(6):918-23. doi: [10.1136/annrheumdis-2012-201643](https://doi.org/10.1136/annrheumdis-2012-201643). [PubMed: [22730371](https://pubmed.ncbi.nlm.nih.gov/22730371/)].

23. Hashimoto S, Fujishiro T, Hayashi S, Kanzaki N, Nishiyama T, Kurosaka M. Clinical importance of impingement deformities for hip osteoarthritis progression in a Japanese population. *Int Orthop*. 2014;**38**(8):1609-14. doi: [10.1007/s00264-014-2393-z](https://doi.org/10.1007/s00264-014-2393-z). [PubMed: [24943460](https://pubmed.ncbi.nlm.nih.gov/24943460/)]. [PubMed Central: [PMC4115094](https://pubmed.ncbi.nlm.nih.gov/PMC4115094/)].
24. Thomas GE, Palmer AJ, Batra RN, Kiran A, Hart D, Spector T, et al. Subclinical deformities of the hip are significant predictors of radiographic osteoarthritis and joint replacement in women. A 20 year longitudinal cohort study. *Osteoarthritis Cartilage*. 2014;**22**(10):1504-10. doi: [10.1016/j.joca.2014.06.038](https://doi.org/10.1016/j.joca.2014.06.038). [PubMed: [25047637](https://pubmed.ncbi.nlm.nih.gov/25047637/)].
25. Kappe T, Kocak T, Neuerburg C, Lippacher S, Bieger R, Reichel H. Reliability of radiographic signs for acetabular retroversion. *Int Orthop*. 2011;**35**(6):817-21. doi: [10.1007/s00264-010-1035-3](https://doi.org/10.1007/s00264-010-1035-3). [PubMed: [20455060](https://pubmed.ncbi.nlm.nih.gov/20455060/)]. [PubMed Central: [PMC3103958](https://pubmed.ncbi.nlm.nih.gov/PMC3103958/)].
26. Werner CM, Copeland CE, Ruckstuhl T, Stromberg J, Turen CH, Kalberer F, et al. Radiographic markers of acetabular retroversion: correlation of the cross-over sign, ischial spine sign and posterior wall sign. *Acta Orthop Belg*. 2010;**76**(2):166-73. [PubMed: [20503941](https://pubmed.ncbi.nlm.nih.gov/20503941/)].
27. Ecker TM, Tannast M, Puls M, Siebenrock KA, Murphy SB. Pathomorphologic alterations predict presence or absence of hip osteoarthrosis. *Clin Orthop Relat Res*. 2007;**465**:46-52. doi: [10.1097/BLO.0b013e318159a998](https://doi.org/10.1097/BLO.0b013e318159a998). [PubMed: [17891037](https://pubmed.ncbi.nlm.nih.gov/17891037/)].
28. Scheidt RB, Galia CR, Diesel CV, Rosito R, Macedo CA. Prevalence of radiographic markers of femoroacetabular impingement in asymptomatic adults. *Rev Col Bras Cir*. 2014;**41**(1):36-42. doi: [10.1590/S0100-69912014000100008](https://doi.org/10.1590/S0100-69912014000100008). [PubMed: [24770772](https://pubmed.ncbi.nlm.nih.gov/24770772/)].
29. Nepple JJ, Lehmann CL, Ross JR, Schoenecker PL, Clohisy JC. Coxa profunda is not a useful radiographic parameter for diagnosing pincer-type femoroacetabular impingement. *J Bone Joint Surg Am*. 2013;**95**(5):417-23. doi: [10.2106/JBJS.K.01664](https://doi.org/10.2106/JBJS.K.01664). [PubMed: [23467864](https://pubmed.ncbi.nlm.nih.gov/23467864/)].
30. Boese CK, Dargel J, Oppermann J, Eysel P, Scheyerer MJ, Bredow J, et al. The femoral neck-shaft angle on plain radiographs: a systematic review. *Skeletal Radiol*. 2016;**45**(1):19-28. doi: [10.1007/s00256-015-2236-z](https://doi.org/10.1007/s00256-015-2236-z). [PubMed: [26305058](https://pubmed.ncbi.nlm.nih.gov/26305058/)].
31. Bouyer B, Mazieres B, Guillemin F, Bouttier R, Fautrel B, Morvan J, et al. Association between hip morphology and prevalence, clinical severity and progression of hip osteoarthritis over 3 years: The knee and hip osteoarthritis long-term assessment cohort results. *Joint Bone Spine*. 2016;**83**(4):432-8. doi: [10.1016/j.jbspin.2015.09.005](https://doi.org/10.1016/j.jbspin.2015.09.005). [PubMed: [26832187](https://pubmed.ncbi.nlm.nih.gov/26832187/)].
32. Morvan J, Bouttier R, Mazieres B, Verrouil E, Pouchot J, Rat AC, et al. Relationship between hip dysplasia, pain, and osteoarthritis in a cohort of patients with hip symptoms. *J Rheumatol*. 2013;**40**(9):1583-9. doi: [10.3899/jrheum.121544](https://doi.org/10.3899/jrheum.121544). [PubMed: [23858046](https://pubmed.ncbi.nlm.nih.gov/23858046/)].
33. Laborie LB, Lehmann TG, Engesaeter IO, Sera F, Engesaeter LB, Rosendahl K. The alpha angle in cam-type femoroacetabular impingement: new reference intervals based on 2038 healthy young adults. *Bone Joint J*. 2014;**96-B**(4):449-54. doi: [10.1302/0301-620X.96B4.32194](https://doi.org/10.1302/0301-620X.96B4.32194). [PubMed: [24692609](https://pubmed.ncbi.nlm.nih.gov/24692609/)].
34. Stea S, Bordini B, Viceconti M, Traina F, Cervini A, Toni A. Is laterality associated with a higher rate of hip arthroplasty on the dominant side? *Artif Organs*. 2008;**32**(1):73-7. doi: [10.1111/j.1525-1594.2007.00457.x](https://doi.org/10.1111/j.1525-1594.2007.00457.x). [PubMed: [18181807](https://pubmed.ncbi.nlm.nih.gov/18181807/)].
35. Newton J, Seagroatt V. Why is osteoarthritis of the hip more common on the right? *Lancet*. 1993;**341**(8838):179. doi: [10.1016/0140-6736\(93\)90045-I](https://doi.org/10.1016/0140-6736(93)90045-I). [PubMed: [8093777](https://pubmed.ncbi.nlm.nih.gov/8093777/)].