



# Pyosalpinx in a Virgin Female Patient Misdiagnosed with Adnexal Torsion: A Case Report and Narrative Review

Seyyedeh Neda Kazemi<sup>1</sup>, Maliheh Arab<sup>2,\*</sup>, Maryamossadat Hosseini<sup>2</sup>, Shahla Noori Ardebili<sup>3</sup> and Nasrin Yousefi<sup>4</sup>

<sup>1</sup>Gynecology and Obstetrics Ward, Shahid Beheshti University of Medical Sciences, Tehran, Iran

<sup>2</sup>Cancer Research Center, Shahid Beheshti University of Medical Sciences, Tehran, Iran

<sup>3</sup>Gynecologist and Obstetrician, Laparoscopist, Tehran, Iran

<sup>4</sup>Master of Developmental Biology, Tehran, Iran

\*Corresponding author: Professor of Gynecology-Oncology, Cancer Research Center, Shahid Beheshti University of Medical Sciences, Tehran, Iran. Email: drmarab@sbmu.ac.ir

Received 2019 February 25; Revised 2019 April 30; Accepted 2019 May 01.

## Abstract

**Introduction:** Pelvic inflammatory disease (PID) is an infection of the upper genital tract often caused by ascending sexually transmitted infection. However, this condition is very rare in preadolescent and adolescent virgin females who are not sexually active. Pyosalpinx is a complication of PID and a cause of acute abdominal pain misdiagnosed due to similar abdominal emergencies.

**Case Presentation:** A 14-year-old virgin female patient was admitted to the Emergency Department of a secondary care general Hospital in Birjand City, South Khorasan Province, Iran, in 2017. She presented with abdominal pain, nausea, vomiting, and fever started two days earlier. She had no history of vaginal discharge. Ultrasound findings indicated enlargement of the right ovary and a hypo-echogenic mass surrounded by a fluid; adnexal torsion suspected. Another cystic lesion with a thick wall and 14 mm diameter was detected in the left ovary. The patient underwent appendectomy four years earlier. Laparotomy performed due to acute abdomen and pyosalpinx was real diagnosis. The PubMed, Scopus, Clinical Key, and Up To Date were searched for articles published in the English language up to 2017, using various combinations of the following keywords (MeSH terms were not used): pyosalpinx, virgin, intact, entire, virtuous, Vestal, pure, and maiden.

**Conclusions:** Although rare, it is important to keep the pelvic infection in mind in the differential diagnosis of virgin female patients presenting with clinical symptoms of an acute abdomen, especially in the ones with the history of gastrointestinal and urinary tract infection or surgery.

**Keywords:** Pelvic Inflammatory Disease, Pyosalpinx, Virgin, Active Abdomen, Abscess

## 1. Introduction

Pelvic inflammatory disease (PID) refers to acute infection of the upper genital tract in females and involves any or all of the genital organs such as the uterus, oviducts, and ovaries. This is sometimes accompanied by involvement of the neighboring pelvic organs (1). Sexually transmitted agents such as *Neisseria gonorrhoeae* and *Chlamydia trachomatis* are often implicated in PID, although vaginal flora may also play an important role. Postoperative pelvic cellulitis and abscess, pregnancy-related pelvic infection, and pelvic infection secondary to the spread of another infection produce very similar clinical pictures, and some clinicians refer to all of these as PID (2, 3). However, although PID is classified as a sexually transmitted infection, on rare occasions, it is also observed in female patients with no experience of sexual intercourse. New data from female pa-

tients with a clinical diagnosis of PID indicate that almost 70% of the patients have non-C. trachomatis/non-N. gonorrhoeae infections. The pelvic inflammatory disease has particular importance for clinical and public health, since it is associated with significant short- and long-term sequelae. Prompt diagnosis and treatment are essential to reduce the risk of both complications. However, even with timely treatment and clinical improvement of symptoms, long-term sequelae frequently occur; this is thought to be secondary to the scarring and adhesion formation that accompanies the healing of infection and damaged tissue. These sequelae namely, chronic pelvic pain, infertility, and ectopic pregnancy account for much of the morbidity, suffering, and cost of PID (4).

Short-term sequelae includes the development of TOA (tubo-ovarian abscess) and pyosalpinx, perihepatitis, and periappendicitis TOA and pyosalpinx are serious and po-

tentially life-threatening conditions. Approximately one-third of female patients hospitalized with a diagnosis of PID have a TOA (5). The mechanism of TOA formation is not fully elucidated. However, TOA most frequently results from upper genital tract infection, but can also arise from focal spread from adjacent organs, adnexal surgery, and occasionally from the hematologic spread. It is unclear why a minority of females with genital tract infection develop TOA. Intrinsic or infection-derived tubal abnormalities or damage to the tube during other surgery predisposes the patient to TOA (1, 2, 4, 6).

In a review by Cho et al., in Korea, 4.1% of the patients with PID were virgin (7). Upon the review of such patients and similar articles, the source of infection was usually ascending and seldom hematogenous. Recurrent urinary infection was the main risk factor in the history of patients, and the most frequently isolated microorganism was *Escherichia coli*, followed by *Streptococcus* spp. In some cases of PID among virgin female patients, there was a history of abdominopelvic surgery such as for congenital bowel abnormality, fecal incontinence, or appendectomy owing to a perforated appendix. Possible causes of PID include postsurgical complications and congenital defects such as salpinges dysmotility owing to an innervation disorder or damage to ciliated mucosal cells (6, 8-10).

As a whole, there were limited studies on PID in virgin female patients, most of which were case reports; therefore, the current study aimed at presenting a case of PID in a virgin female patient and reviewing some similar cases in the literature.

## 2. Case Presentation

A 14-year-old virgin female patient, born to a healthy mother, was admitted to the Emergency Department of Shohadaye Ghaen secondary care general Hospital in Birjand, South Khorasan Province, Iran, in year 2017. She had a sudden increasing lower abdominal pain, nausea, and vomiting since the previous day. She had no previous symptoms and no history of vaginal discharge. She had regular menstrual cycles and was on the 10th day of her cycle.

She had an open appendectomy four years earlier due to perforated appendicitis. In the physical examination, the temperature was 39.2°C, pulse rate 120 beats per minute, and blood pressure 104/65 mmHg. She presented with abdominal rebound tenderness and guarding, and normal bowel sounds. A gynecologic examination was normal, with an intact hymen. Laboratory results showed leukocytosis and a negative pregnancy test. Ultrasound examination revealed enlargement of the right ovary, with a mass-like hypoechogenic appearance surrounded by a

fluid, in favor of adnexal torsion. Another cystic lesion, with a thick wall and 14 mm diameter was found in the left ovary with a normal Color Doppler ultrasonography. Owing to concerns about adnexal torsion, a gynecologic consultation was carried out, and due to rebound tenderness and guarding, an emergency laparotomy was performed for a suspected ovarian torsion with a low midline incision. Surgical findings showed 200 mL pus in the abdomen. The uterus, left and right ovaries, left salpinx, and proximal right salpinx were unremarkable, and no adnexal torsion existed. An enlarged erythematous end loop similar to intestine was observed on the right side of the pelvis, in addition to several adhesion bands, without any other pathology. Adhesiolysis and abdominal exploration were performed after widening the incision. The right Fallopian tube was grossly enlarged and tortuous for about 20 cm (Figure 1). After salpingostomy, massive pus poured out of the tube. The tube and abdominal area were irrigated with normal saline (Figure 2). Intravenous ceftriaxone and metronidazole were administered, and drainage was also continued for four days, followed by oral antibiotics for 10 days. *Escherichia coli* sensitive to ceftriaxone were detected in the microbiological pus sample. The pathologic report of Fallopian tube biopsy revealed severe inflammation. In the gynecological examination 10 days later, the patient was in good general health without any complaints or noticeable problems.

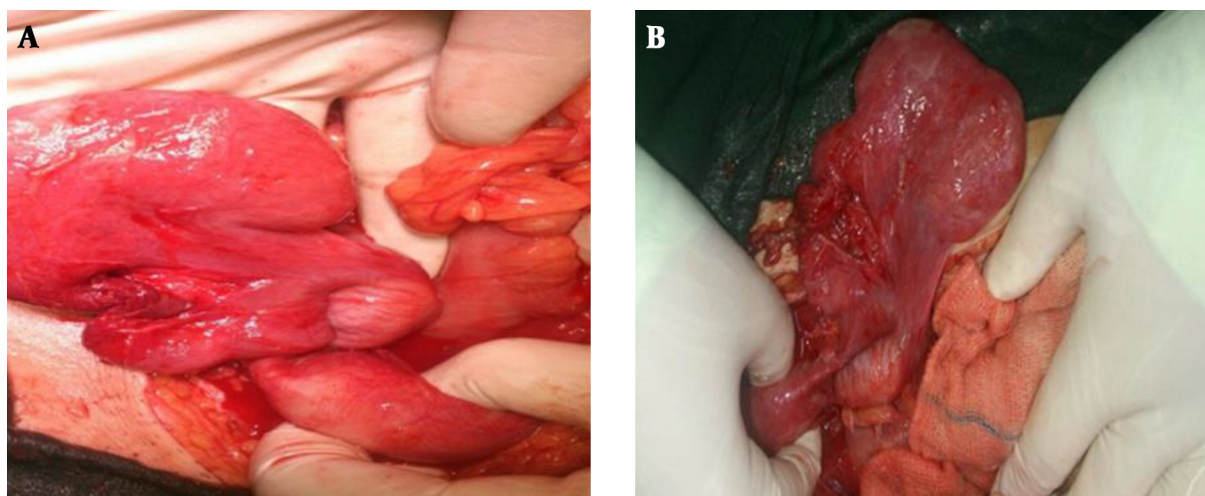
Informed consent was obtained from the patient to publish the report; the study was conducted in accordance with the principles of the Declaration of Helsinki. The study protocol was also approved by the Ethics Committee of Shahid Beheshti University of Medical Sciences, Tehran, Iran.

### 2.1. Search Strategies

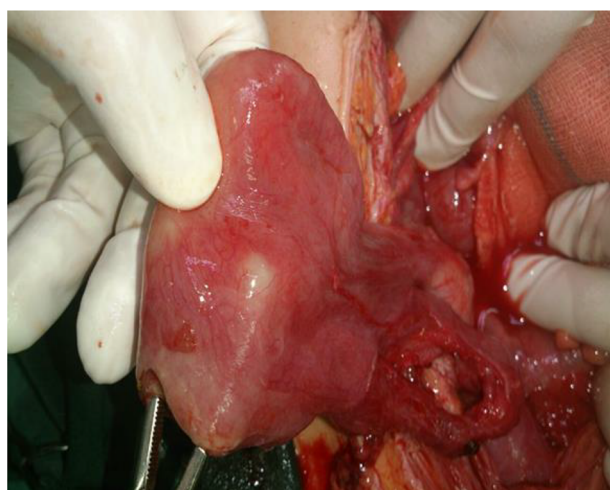
The PubMed, SCOPUS, Clinical Key, and UpToDate databases were searched for articles published in the English language until 2017, using various combinations of the following keywords: pyosalpinx, virgin, intact, entire, virtuous, Vestal, pure, and maiden. In addition, the references of all relevant articles found in the search were reviewed.

## 3. Discussion

PID and TOA are rare in virgin female patients; however, they should be considered in all female cases with abdominal pain, regardless of sexual history. A summary of the literature review with respect to TOA among 24 virgin female patients is presented in Table 1 (7, 11-29). In this review, 12 out of 24 cases were pyosalpinx, similar to the current case. The mean age of patients was 17 years; ranged 26



**Figure 1.** In the 14-year-old female patient, the right Fallopian tube was markedly distended with pyosalpinx.



**Figure 2.** Right salpingostomy was performed.

days (newborn) to 47 years. The first presentation was abdominal pain in 18 (75%) cases; abdominal pain with fever in three (12%) cases; and fatigue, vaginal discharge, and diarrhea in one (4%) case. Clinical symptoms varied as follows: abdominal pain in 21 (87.5%) cases, nausea and vomiting in eight (33%), anorexia in four (17%), diarrhea in three (12.5%), vaginal discharge in six (25%), urinary symptoms in four (17%), and fever in 17 (71%) cases. Mean patient temperature was 38.1°C and the maximum was 39.6°C. The most prolonged duration of fever from the onset of illness to diagnosis was three months with the mean duration of 12.5 days. A total of 20 out of 24 (91%) patients demonstrated

leukocytosis in blood test results, with a mean and maximum of 15537 and 26750 WBC/mL, respectively. Abscess formation was right-sided in 12 out of 23 (54%) cases, left-sided in six (27%), and bilateral in four (18%) cases. Pyosalpinx was recorded in 12 cases (50%), similar to the current case. The most frequent microorganism isolated from pus culture was *E. coli* in 12 out of 22 (58%) cases. In six out of 24 (25%) cases, the correct preoperative diagnosis measures were taken. The most common preoperative diagnosis was ovarian mass in 12 (50%) cases. In 12 (50%) virgin female patients with TOA, there was a history of surgery or other predisposing factors. All patients received antibiotic therapy, and in some cases, surgical procedures were also performed. There was only one death reported; a 26-day-old patient, owing to systemic involvement and delay in diagnosis. The clinical presentation of TOA tends to be nonspecific and includes lower abdominal pain, fever, chills, as well as vaginal discharge in fewer than 5% of patients. Imaging studies are a crucial component to diagnose TOA, and ultrasound is typically the first-line imaging study. The typical appearance of TOA is a multilocular, cystic, and complex adnexal mass often with debris and thick septations. Computed tomography may also be used, particularly when pathology of the gastrointestinal tract should be excluded (11-29).

In the current case, a virgin female patient was presented with abdominal pain, fever, and signs of peritonitis. Sonography revealed an adnexal mass, probably compatible with a diagnosis of adnexal torsion; as the cause of acute abdomen. Therefore, laparotomy was performed. For future fertility preservation, laparoscopy might have been considered for diagnosis. In the minimally invasive procedure, immediate drainage of the abscess is possible

**Table 1.** Review of Twenty-Four Virgin Female Patients with TOA

Author	Age of Patient, y	Mass Size, cm	Pre-Operation Diagnosis	Concomitant Condition	History of Surgery
Claireaux et al. (14)	26 (d)	4 × 2	Embrioma	Admitted to NICU	
Teng et al. (26)	47	No evidence	Tubo-ovarian abscess	Endometrioma and trauma	Hysterectomy with bilateral salpingo-oophorectomy and appendectomy
Habek et al. (20)	9	3 × 4	Peritonitis of unknown etiology		Right-sided salpingectomy and appendectomy and pelvic lavage
Fumino et al. (17)	13	10	Tubo-ovarian abscess	Colonic vaginoplasty for high cloacal anomaly	left salpingo-oophorectomy
Arda et al. (11)	15	6 × 2.5 × 3	Tubo-ovarian abscess	Appendectomy	Right salpingostomy with drainage
Dogan et al. (16)	19	5.7 × 7.6 × 9.1	Ovarian tumor		Abscess drainage
van der Putten et al. (28)	11		Perforated appendicitis		
Singh-Ranger et al. (25)	17		Complex pelvic mass	Appendectomy	Retrograde milking of pus from tube
Hornemann et al. (21)	13	7 × 5 × 8	Complex pelvic mass		Salpingectomy
Gensheimer et al. (18)	20	7 × 5	Hemorrhagic cyst		Salpingo-oophorectomy and appendectomy
Sakar et al. (23)	13	7 × 7	Ovarian tumor		Abscess drainage
Ashrafganjooei et al. (12)	24	7 × 7.5	Pelvic tumor	Transverse vaginal septum	Hysterectomy with bilateral salpingo-oophorectomy
Desai and Ward (15)	12	No evidence	Pyosalpinx	Colostomy and appendectomy due to the Hirschsprung disease	
Simpson-Camp et al. (24)	14	12.5 × 9 × 11	Ovarian tumor		Irrigation of abscess cavity
Tuncer et al. (27)	17	19 × 11 in left and 8.5 × 10 in right	Tubo-ovarian abscess	Diverticulitis	Percutaneous drainage
Moralioglu et al. (22)	14	10.5 × 7.5	Cystic mass	Perineal pull-through procedure and genitourinary anomaly	Salpingectomy
Goodwin et al. (19)	13	10	Small bowel obstruction	Appendectomy	Drainage
Cheong and Emil (29)		10 × 3 × 11.4	Abscess due to perforated appendicitis		Salpingectomy+ left ovary debridement
Carolin Schmiegl and Bertram Reingruber (13)	12	7 × 9	Small bowel obstruction	Appendectomy	Salpingostomy
Cho et al. (7)	14	7	Dermoid cyst or pyelonephritis	Right pyosalpinx	Right salpingostomy with drainage
Cho et al. (7)	21	3.6	Ruptured corpus luteum	Appendectomy	Abscess drainage with appendectomy
Cho et al. (7)	20	4.5 × 4.5	Tubo-ovarian abscess	Bilateral pyosalpinx	Abscess drainage
Cho et al. (7)	24	15	Endometrioma	Cul-de-sac abscess with left pyosalpinx	Abscess drainage
Cho et al. (7)	23	2.6	Bilateral endometrioma	Bilateral pyosalpinx	Abscess drainage with appendectomy

after diagnosis, which may allow for a more rapid recovery and likely result in better preservation of fertility.

In conclusion, in virgin cases, the pelvic abscess should be considered, especially in the ones with the history of gastrointestinal tract surgery.

## Footnotes

**Conflict of Interests:** The authors declared no conflict of interest.

**Ethical Approval:** The study protocol was approved by the Ethics Committee of Shahid Beheshti University of Medical Sciences, Tehran, Iran.



**Funding/Support:** There was no financial support for the study.

**Patient Consent:** Informed consent was obtained from the patient to publish the report.

## References

1. Brook I. Microbiology and management of polymicrobial female genital tract infections in adolescents. *J Pediatr Adolesc Gynecol.* 2002;**15**(4):217-26. [PubMed: 12459228].
2. Gradison M. Pelvic inflammatory disease. *Am Fam Physician.* 2012;**85**(8):791-6. [PubMed: 22534388].
3. Trent M. Pelvic inflammatory disease. *Pediatr Rev.* 2013;**34**(4):163-72. doi: 10.1542/pir.34-4-163. [PubMed: 23547062]. [PubMed Central: PMC4530285].
4. Lareau SM, Beigi RH. Pelvic inflammatory disease and tubo-ovarian abscess. *Infect Dis Clin North Am.* 2008;**22**(4):693-708. doi: 10.1016/j.idc.2008.05.008. [PubMed: 18954759].
5. Simms I, Stephenson JM. Pelvic inflammatory disease epidemiology: What do we know and what do we need to know? *Sex Transm Infect.* 2000;**76**(2):80-7. doi: 10.1136/sti.76.2.80. [PubMed: 10858707]. [PubMed Central: PMC1758284].
6. Walker CK, Wiesenfeld HC. Antibiotic therapy for acute pelvic inflammatory disease: The 2006 centers for disease control and prevention sexually transmitted diseases treatment guidelines. *Clin Infect Dis.* 2007;**44** Suppl 3:S111-22. doi: 10.1086/511424. [PubMed: 17342664].
7. Cho HW, Koo YJ, Min KJ, Hong JH, Lee JK. Pelvic inflammatory disease in virgin women with tubo-ovarian abscess: A single-center experience and literature review. *J Pediatr Adolesc Gynecol.* 2017;**30**(2):203-8. doi: 10.1016/j.jpog.2015.08.001. [PubMed: 26260586].
8. Brun JL, Graesslin O, Fauconnier A, Verdon R, Agostini A, Bourret A, et al. Updated French guidelines for diagnosis and management of pelvic inflammatory disease. *Int J Gynaecol Obstet.* 2016;**134**(2):121-5. doi: 10.1016/j.ijgo.2015.11.028. [PubMed: 27170602].
9. Granberg S, Gjelland K, Ekerhovd E. The management of pelvic abscess. *Best Pract Res Clin Obstet Gynaecol.* 2009;**23**(5):667-78. doi: 10.1016/j.bpobgyn.2009.01.010. [PubMed: 19230781].
10. Rosen M, Breitkopf D, Waud K. Tubo-ovarian abscess management options for women who desire fertility. *Obstet Gynecol Surv.* 2009;**64**(10):681-9. doi: 10.1097/OGX.0b013e3181b8b0d6. [PubMed: 19772677].
11. Arda IS, Ergeneli M, Coskun M, Hicsonmez A. Tubo-ovarian abscess in a sexually inactive adolescent patient. *Eur J Pediatr Surg.* 2004;**14**(1):70-2. doi: 10.1055/s-2004-815786. [PubMed: 15024685].
12. Ashrafjanjooei T, Harirchi I, Iravanlo G. Tubo-ovarian abscess in a virgin girl. *Iran J Reprod Med.* 2011;**9**(3):247-50. [PubMed: 26396572]. [PubMed Central: PMC4575762].
13. Carolin Schmiege ME, Bertram Reingruber KC. Bilateral pyosalpinx as a rare cause of pelvic cystic lesions in a 12-year old girl. *J Pediatr Surg Spe.* 2014;**8**(2):34-8.
14. Claireaux AE, Farquhar JW. A case of pyosalpinx in a newborn infant. *Arch Dis Child.* 1949;**24**(117):62-6. doi: 10.1136/adc.24.117.62. [PubMed: 18114488]. [PubMed Central: PMC1988207].
15. Desai B, Ward T. Bilateral pyosalpinx in a peripubescent female with Hirschsprung's disease: A case report. *Int J Emerg Med.* 2011;**4**(1):64. doi: 10.1186/1865-1380-4-64. [PubMed: 21992509]. [PubMed Central: PMC3206412].
16. Dogan E, Altunyurt S, Altindag T, Onvural A. Tubo-ovarian abscess mimicking ovarian tumor in a sexually inactive girl. *J Pediatr Adolesc Gynecol.* 2004;**17**(5):351-2. doi: 10.1016/j.jpog.2004.07.002. [PubMed: 15581782].
17. Fumino S, Iwai N, Tokiwa K, Hibi M, Iwabuchi T. Tubo-ovarian abscess after colonic vaginoplasty for high cloacal anomaly in a 13-year-old girl. *Eur J Pediatr Surg.* 2002;**12**(5):345-7. doi: 10.1055/s-2002-35960. [PubMed: 12469265].
18. Gensheimer WG, Reddy SY, Mulconry M, Greves C. Abiotrophia/Granulicella tubo-ovarian abscess in an adolescent virginal female. *J Pediatr Adolesc Gynecol.* 2010;**23**(1):e9-12. doi: 10.1016/j.jpog.2009.05.007. [PubMed: 19682931].
19. Goodwin K, Fleming N, Dumont T. Tubo-ovarian abscess in virginal adolescent females: A case report and review of the literature. *J Pediatr Adolesc Gynecol.* 2013;**26**(4):e99-102. doi: 10.1016/j.jpog.2013.02.004. [PubMed: 23566794].
20. Habek D, Vranko Nagy N, Sklebar I, Grabovac S, Cerkez Habek J. Rupture of coliform pyosalpinx in a nine-year old girl. *Zentralbl Gynakol.* 2002;**124**(4):220-2. doi: 10.1055/s-2002-32429. [PubMed: 12080484].
21. Hornemann A, von Koschitzky H, Bohlmann MK, Hornung D, Diedrich K, Taffazoli K. Isolated pyosalpinx in a 13-year-old virgin. *Fertil Steril.* 2009;**91**(6):2732 e9-10. doi: 10.1016/j.fertnstert.2008.12.143. [PubMed: 19230877].
22. Moralioglu S, Ozen IO, Demirogullari B, Basaklar AC. Pyosalpinx and hydrosalpinx in virginal adolescents: Report of two cases. *West Indian Med J.* 2013;**62**(3):257-9. [PubMed: 24564050].
23. Sakar MN, Gul T, Atay AE. Tubo-ovarian abscess presenting as an ovarian tumor in a virginal adolescent: A case report. *Clin Exp Obstet Gynecol.* 2012;**39**(3):388-9. [PubMed: 23157053].
24. Simpson-Camp L, Richardson EJ, Alaish SM. Streptococcus viridans tubo-ovarian abscess in an adolescent virgin. *Pediatr Int.* 2012;**54**(5):706-9. doi: 10.1111/j.1442-200X.2012.03569.x. [PubMed: 23005903].
25. Singh-Ranger D, Sanusi A, Hamo I. Coliform pyosalpinx as a rare complication of appendicectomy: A case report and review of the literature on best practice. *J Med Case Rep.* 2008;**2**:97. doi: 10.1186/1752-1947-2-97. [PubMed: 18384683]. [PubMed Central: PMC2311322].
26. Teng FY, Cardone JT, Au AH. Pasteurella multocida tubo-ovarian abscess in a virgin. *Obstet Gynecol.* 1996;**87**(5 Pt 2):883. [PubMed: 8677128].
27. Tuncer ZS, Boyraz G, Yucel SO, Selcuk I, Yazicioglu A. Tuboovarian abscess due to colonic diverticulitis in a virgin patient with morbid obesity: A case report. *Case Rep Med.* 2012;**2012**:413185. doi: 10.1155/2012/413185. [PubMed: 22952477]. [PubMed Central: PMC3431136].
28. van der Putten ME, Engel M, van Well GT. Salpingitis. A rare cause of acute abdomen in a sexually inactive girl: A case report. *Cases J.* 2008;**1**(1):326. doi: 10.1186/1757-1626-1-326. [PubMed: 19017411]. [PubMed Central: PMC2602995].
29. Cheong LHA, Emil S. Non-sexually transmitted tubo-ovarian abscess in an adolescent. *J Pediatr Surg Case Rep.* 2013;**1**(10):378-80. doi: 10.1016/j.epsc.2013.10.005.