



A Successfully Managed Case of Corneal Bee Sting: A Case Report and Literature Review

Xin-Xuan Dai¹, Ji-Long Hao¹, Dan-Dan Zhou², Si-Ying Teng¹, Peng Hui¹ and Cheng-Wei Lu^{1,*}

¹Department of Ophthalmology, The First Hospital of Jilin University, Changchun, China

²Department of Radiology, The First Hospital of Jilin University, Changchun, China

*Corresponding author: Department of Ophthalmology, The First Hospital of Jilin University, No. 71 of Xinmin St., Changchun, China, Tel: +86-15904425848, Email: lcwchina800@sina.com

Received 2019 November 03; Accepted 2019 December 21.

Abstract

Introduction: Bee sting to the cornea is a relatively rare environmental injury that can result in vision loss of different degrees. This study aimed to review the clinical features, pathogenesis, and management of keratopathy caused by corneal bee sting and present a case of keratitis with hypopyon and iridocyclitis secondary to bee sting injury without a retained stinger.

Case Presentation: A 47-year-old man was presented for eyelid edema, severe pain, redness, and impaired vision following a corneal bee sting. On examination, we observed striate keratitis, focal infiltration with diffuse corneal edema, and iridocyclitis under the slit lamp. We also noted trace cells and empyema in the anterior chamber prompted by infection. No retained stinger was detected. A treatment strategy with corticosteroids in combination with broad-spectrum topical antibiotics started and the symptoms resolved significantly. At a three-week follow-up, the cornea restored transparency without complications and visual acuity maintained 20/20.

Conclusions: Following bee sting injury, it is crucial to monitor the progression, manifestations, and development of inflammation and infection. Individual timing, symptoms, severity, and complications vary in each case due to various compositions of bee venom. Therefore, assessment and careful follow-up of evolving manifestations may lead to better therapeutic decisions.

Keywords: Keratitis, Bee Sting, Iris Discoloration, Treatment

1. Introduction

Bee sting to the cornea is a relatively rare environmental injury, resulting in vision loss of different degrees. Although rarely reported in the ophthalmological literature, a corneal bee sting can give rise to serious ocular impairment. Some case reports have documented immunological and toxic reactions to the venom injected by bee stinger. Symptoms caused by anaphylaxis and secondary infection vary from local swelling and discomfort at the site of sting to significant complications, resulting in corneal infiltrates, edema, bullous keratitis, striate keratopathy, chemosis, iris atrophy, hyphemia, ciliary injection, anterior uveitis, anterior/posterior capsular opacities of the lens, lens subluxation, cataract, and optic neuritis (1, 2). The manifestations can be variable; therefore, close observation is needed. The standard management of bee sting injury remains controversial because the infection may aggravate following the administration of antibiotics concomitant with steroids. The therapeutic decisions should be adjusted according to the emerging symptoms.

Here, we describe a successfully treated case of keratitis, hypopyon, and iridocyclitis in an acute period secondary to bee sting injury without a retained stinger, for which the ocular presentation recovered to normal after a course of treatment.

2. Case Presentation

A 47-year-old man presented with redness, eyelid swelling, severe ocular pain, and decreased vision in the right eye for one day resulting from bee sting injury while praying the ancestors in the suburbs. The patient had a past history of glaucoma surgery 10 years ago in both eyes. Visual acuity (VA) in the right eye and left eye was 20/200 and 20/20, respectively.

Slit-lamp examination of the affected eye revealed ciliary congestion, conjunctival chemosis, and corneal edema together with Descemet membrane fold. There was a white cloudy lesion at the nine o'clock region of the corneal limbus. Aqueous flare with the 1.5 mm level of hypopyon was noticed obviously (Figure 1A, arrow). The

posterior segment could not be observed due to the hazy cornea. No abnormality of the left eye was visualized. Surgical exploration was done immediately; however, no retained stinger was detected. Confocal corneal microscopy of the right eye showed larger endothelial cells with loss of normal contour. Dark areas with low reflection could be seen in the rear stroma. Postoperatively, ophthalmic antibiotics and steroids along with a course of systemic steroid treatment started and tapered gradually over four weeks. The corneal opacity mostly resolved within two weeks but mild edema persisted with iris atrophy (Figure 1B). At a subsequent follow-up of three weeks, the cornea was transparent and there was segmental iris discoloration from four o'clock to nine o'clock due to iris atrophy (Figure 1C, arrow). The VA recovered to 20/20.

3. Discussion

A bee sting is a relatively uncommon environmental injury, which can cause vision impairment to vision loss. Ocular impairments are attributed to either toxic venom effect, immunological effect, mechanical effect, or their combination (3, 4). It is significant that stingers may release venom. In the act of stinging, bees secrete two bodily elements into the eye, including specific venom and chitinase stinger (5-7).

Bee venom is composed of several compounds, including low molecular weight peptides, enzymes, biological amines, and major protein subunits. Bee venom contains complex toxins, which can result in different complications leading to keratopathy, hyphemia, atrophy, cataract, anterior uveitis, optic neuritis, and ophthalmoplegia (4, 8-10). Toxicity is primarily attributed to two series of biological amines found in venom: enzymes (phospholipase A, phospholipase B, and hyaluronidase) and nonenzymatic polypeptide toxins (apamin, iminimine, melittin, and mast-cell degranulating peptide) (11-15).

However, no retained stinger was found in surgical exploration in our case. If the venom gland is still adherent acutely and is manipulated in the retained stinger, the eye contraction of attached muscle fibers will persist, resulting in continued toxicity and additional venom discharge (4). In our patient, only remained the venom in the affected eye without a stinger. Adverse immunological and toxic reactions disappear gradually once the venom injected by bee stinger is neutralized. Non-retained stinger tends to generate better outcomes (16).

As the cornea is located on the surface of the eye, the incidence of corneal damage caused by bee sting injuries is common, mainly presenting with corneal infiltrates, edema, bullous keratitis, and striate keratopathy (3). The

patient presented here showed characteristic striate keratitis and corneal edema. Ang et al. (8) reported characteristic striate keratitis as a pathognomonic feature in bee sting keratopathy observed in their three cases. Acetylcholine in the wasp venom can cause corneal edema (7). It has been explained that the specific mechanism of corneal edema is related to cell death caused by the activation of the complement cascade by proteins found in bee venom, which leads to the occurrence of chemotactic factor and anaphylatoxins (1, 7, 17). The accumulation of apamin, melittin, and biogenic amines gives rise to severe, immediate toxic effects of sting (1, 17).

The standard management of bee sting injury remains controversial. Topical corticosteroids are constantly prescribed to treat iritis although the probability of susceptibility to infection may increase with the application of antibiotics concomitant with steroids (18, 19). It is suggested that steroids be attentively administered under antibiotic coverage if an infection is suspected (20, 21). The application of steroids and antibiotics should be balanced and prudent.

The patient received acute treatment and corticosteroids were used in combination with antibiotics to suppress inflammation caused by the venom. Bullous keratopathy tends to be the end of corneal edema in the cases of wasp sting (6). In our case, the cornea turned out to be diaphanous and inflammation subsided after active treatment. Visual acuity restored with left inferior segment iris discoloration (heterochromia iridis). In our case, it was attributed to the lysis of chromatophores in the layers of the anterior iris by melittin (4, 22). The review of cases with iris atrophy in the published literature is summarized in Table 1.

To sum up, individual timing, symptoms, severity, and complications vary in each case due to various components of bee venom. Thus, bee sting injuries are vital to be monitored for evolving manifestations and development of inflammation and infection. Therapeutic decisions should be adjusted accordingly.

Footnotes

Authors' Contribution: Study concept and design: Cheng-Wei Lu. Analysis and interpretation of data: Xin-Xuan Dai, Ji-Long Hao, and Dan-Dan Zhou. Drafting of the manuscript: Xin-Xuan Dai and Dan-Dan Zhou. Critical revision of the manuscript for important intellectual content: Si-Ying Teng, Peng Hui, and Ji-long Hao.

Conflict of Interests: The authors declare that they have no conflict of interest.

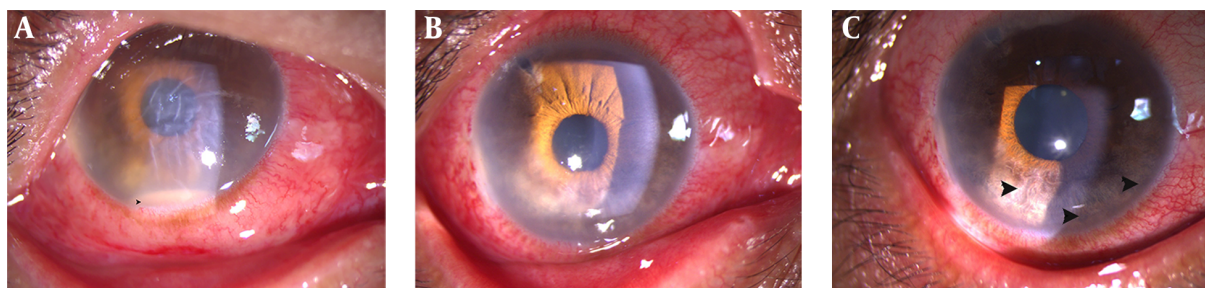


Figure 1. A, Slit-lamp image of the injured eye before topical treatment showing corneal edema together with Descemet membrane fold and hypopyon; B, corneal opacity mostly resolved within two weeks but mild edema persisted with iris atrophy within two weeks; C, at a subsequent follow-up of three weeks, the cornea was transparent and there was segmental iris discoloration from four o'clock to nine o'clock due to iris atrophy.

Table 1. Published Cases of Corneal Bee Sting with Iris Atrophy

Age/sex	Position	Duration	Treatment	Sequel	Pretreatment Vision Acuity	Postoperative Visual Acuity	References
62/M	Central cornea	Corneal edema	Endothelial keratoplasty	White scarring within the corneal stroma	1/60	6/18	(23)
24/M	2 mm from the center of the right eye cornea	3 mm nasal paracentral corneal opacity central necrosis and peripheral infiltration; segmental iris discoloration; pupillary distortion	Ophthalmic antibiotic and steroid	A small opacity of the cornea over the stinger site. segmental iris discoloration	3/10	7/10	(24)
58/M	not mentioned	Inferior vascularization of the stroma, intense corneal edema, inferior iris atrophy, total cataract	Penetrating keratoplasty, extracapsular cataract extraction and intraocular lens implantation	Iris atrophy, pupillary distortion	Light perception	20/30	(6)
35/M	not mentioned	Corneal edema, folds in Descemet's membrane, inferior iris atrophy, inflammation anterior chamber	Topically instilled mydriatic, antibiotic, corticosteroid, penetrating keratoplasty	Corneal edema	Finger count at 40 cm	-	(6)

Ethical Approval: The study followed the tenets of the Declaration of Helsinki. Informed consent was obtained from the patient.

Funding/Support: This study received no specific grant from any funding agency in the public, commercial or not-for-profit sectors.

Informed Consent: Written informed consent was obtained from the patient for the publication of this case report and any accompanying images.

References

- Rai RR, Gonzalez-Gonzalez LA, Papakostas TD, Siracuse-Lee D, Dunphy R, Fanciullo L, et al. Management of corneal bee sting injuries. *Semin Ophthalmol.* 2017;**32**(2):177-81. doi: [10.3109/08820538.2015.1045301](https://doi.org/10.3109/08820538.2015.1045301). [PubMed: [26161915](https://pubmed.ncbi.nlm.nih.gov/26161915/)].
- Gurlu VP, Erda N. Corneal bee sting-induced endothelial changes. *Cornea.* 2006;**25**(8):981-3. doi: [10.1097/01.icc.00000226364.57172.72](https://doi.org/10.1097/01.icc.00000226364.57172.72). [PubMed: [17102681](https://pubmed.ncbi.nlm.nih.gov/17102681/)].
- Chinwattanakul S, Prabhasawat P, Kongsap P. Corneal injury by bee sting with retained stinger—a case report. *J Med Assoc Thai.* 2006;**89**(10):1766-9. [PubMed: [17128856](https://pubmed.ncbi.nlm.nih.gov/17128856/)].
- Smith DG, Roberge RJ. Corneal bee sting with retained stinger. *J Emerg Med.* 2001;**20**(2):125-8. doi: [10.1016/s0736-4679\(00\)00298-5](https://doi.org/10.1016/s0736-4679(00)00298-5). [PubMed: [11207405](https://pubmed.ncbi.nlm.nih.gov/11207405/)].
- Al-Towerki AE. Corneal honeybee sting. *Cornea.* 2003;**22**(7):672-4. doi: [10.1097/00003226-200310000-00011](https://doi.org/10.1097/00003226-200310000-00011). [PubMed: [14508263](https://pubmed.ncbi.nlm.nih.gov/14508263/)].
- Arcieri ES, Franca ET, de Oliveria HB, De Abreu Ferreira L, Ferreira MA, Rocha FJ. Ocular lesions arising after stings by hymenopteran insects. *Cornea.* 2002;**21**(3):328-30. doi: [10.1097/00003226-200204000-00019](https://doi.org/10.1097/00003226-200204000-00019). [PubMed: [11917187](https://pubmed.ncbi.nlm.nih.gov/11917187/)].
- Gilboa M, Gdal-On M, Zonis S. Bee and wasp stings of the eye. Retained intralenticular wasp sting: A case report. *Br J Ophthalmol.* 1977;**61**(10):662-4. doi: [10.1136/bjo.61.10.662](https://doi.org/10.1136/bjo.61.10.662). [PubMed: [588520](https://pubmed.ncbi.nlm.nih.gov/588520/)]. [PubMed Central: [PMC1043080](https://pubmed.ncbi.nlm.nih.gov/PMC1043080/)].
- Ang WJ, Md Kadir SZ, Fadzillah AJ, Zunaina E. A Case series of bee sting keratopathy with different outcomes in Malaysia. *Cureus.* 2017;**9**(2).

- e1035. doi: [10.7759/cureus.1035](https://doi.org/10.7759/cureus.1035). [PubMed: 28357167]. [PubMed Central: PMC5356989].
9. Maltzman JS, Lee AG, Miller NR. Optic neuropathy occurring after bee and wasp sting. *Ophthalmology*. 2000;**107**(1):193-5. doi: [10.1016/s0161-6420\(99\)00020-2](https://doi.org/10.1016/s0161-6420(99)00020-2). [PubMed: 10647742].
 10. Kitagawa K, Hayasaka S, Setogawa T. Wasp sting-induced retinal damage. *Ann Ophthalmol*. 1993;**25**(4):157-8. [PubMed: 8484660].
 11. Yildirim N, Erol N, Basmak H. Bee sting of the cornea: A case report. *Cornea*. 1998;**17**(3):333-4. doi: [10.1097/00003226-199805000-00015](https://doi.org/10.1097/00003226-199805000-00015). [PubMed: 9603391].
 12. Valentine MD. Insect venom allergy: Diagnosis and treatment. *J Allergy Clin Immunol*. 1984;**73**(3):299-304. doi: [10.1016/0091-6749\(84\)90397-x](https://doi.org/10.1016/0091-6749(84)90397-x). [PubMed: 6366028].
 13. Habermann E. Bee and wasp venoms. *Science*. 1972;**177**(4046):314-22. doi: [10.1126/science.177.4046.314](https://doi.org/10.1126/science.177.4046.314). [PubMed: 4113805].
 14. Schmidt JO, Blum MS, Overal WL. Comparative enzymology of venoms from stinging Hymenoptera. *Toxicon*. 1986;**24**(9):907-21. doi: [10.1016/0041-0101\(86\)90091-7](https://doi.org/10.1016/0041-0101(86)90091-7). [PubMed: 3544339].
 15. Sobotka AK, Franklin RM, Adkinson NJ, Valentine M, Baer H, Lichtenstein LM. Allergy to insect stings. II. Phospholipase A: the major allergen in honeybee venom. *J Allergy Clin Immunol*. 1976;**57**(1):29-40. doi: [10.1016/0091-6749\(76\)90076-2](https://doi.org/10.1016/0091-6749(76)90076-2). [PubMed: 54382].
 16. Tuft SJ, Crompton DO, Coster DJ. Insect sting in a cornea. *Am J Ophthalmol*. 1985;**99**(6):727-8. doi: [10.1016/s0002-9394\(14\)76051-9](https://doi.org/10.1016/s0002-9394(14)76051-9).
 17. Chen CJ, Richardson CD. Bee sting-induced ocular changes. *Ann Ophthalmol*. 1986;**18**(10):285-6. [PubMed: 3490817].
 18. DeBroff BM, Donahue SP, Caputo BJ, Azar MJ, Kowalski RP, Karenchak LM. Clinical characteristics of corneal foreign bodies and their associated culture results. *CLAO J*. 1994;**20**(2):128-30. [PubMed: 8044979].
 19. Nishimoto JY. Iritis. How to recognize and manage a potentially sight-threatening disease. *Postgrad Med*. 1996;**99**(2):255-7. 261-2. [PubMed: 8632971].
 20. Lin PH, Wang NK, Hwang YS, Ma DH, Yeh LK. Bee sting of the cornea and conjunctiva: Management and outcomes. *Cornea*. 2011;**30**(4):392-4. doi: [10.1097/ICO.0b013e3181f234a6](https://doi.org/10.1097/ICO.0b013e3181f234a6). [PubMed: 21099408].
 21. Razmjoo H, Abtahi MA, Roomizadeh P, Mohammadi Z, Abtahi SH. Management of corneal bee sting. *Clin Ophthalmol*. 2011;**5**:1697-700. doi: [10.2147/OPTH.S26919](https://doi.org/10.2147/OPTH.S26919). [PubMed: 22174578]. [PubMed Central: PMC3236715].
 22. Singh G. Bee sting of the cornea. *Ann Ophthalmol*. 1984;**16**(4):320-2.
 23. Olivo Payne A, Chong E. Bee sting to the cornea: Toxic effects and management. *Med J Aust*. 2018;**209**(4):155. [PubMed: 30107768].
 24. Fard AM, Pourafkari L, Nader ND. Cornea bee sting. *QJM*. 2015;**108**(11):911. doi: [10.1093/qjmed/hcv090](https://doi.org/10.1093/qjmed/hcv090). [PubMed: 26001401].