

Primary Hydatid Disease of the Ilium: A Case Report

MJ Emami^{1*}, AR Vosoughi¹, I Vadiie¹, S Pakbaz², S Liaghat¹

¹Department of Orthopaedic Surgery, Research Center for Bone and Joint Diseases, ² Department of Pathology, Chamran Hospital, Shiraz University of Medical Sciences, Shiraz, Iran

Abstract

Bone hydatid disease is endemic in several regions worldwide and lacks a typical clinical appearance and image characteristics; therefore, its diagnosis is very difficult. A 49-year-old rural woman was referred with purulent discharge from sinus tract in the left ilium. X-ray and CT scan showed multiple lytic lesions with cortical destruction. She was scheduled for sequestrectomy with impression of chronic osteomyelitis but destroyed hydatid cysts were detected intraoperatively. Iliac wing excision from the iliac crest to the sacroiliac joint and supracetabulum area was performed. Pathologic findings were in favor of bone hydatidosis. Postoperatively, albendazole and antibiotics were prescribed.

Keywords: *Echinococcus granulosus*; Hydatid Disease; Bone Cyst

Introduction

Hydatid disease is relatively common in the Middle East, Mediterranean, Central Asia, East Africa, Russia and South America.¹ The disease is caused by a parasite tapeworm, named *Echinococcus*, with two species that affect man. *E. granulosus* and *E. multilocularis* result in cystic hydatid disease and alveolar hydatid disease, respectively.¹⁻³ The parasite lives in the small intestine of dogs, foxes and other carnivores as definite hosts.¹ Infected ova after shedding in faeces are swallowed by humans or sheep as intermediate hosts. After ingestion of the outer coat of the ovum in the stomach, the larvae is released and enter the circulation through the portal vein and spread to various organs.^{2,3} They commonly involve the liver (68-75% of all cases) and the lung (15-25%).⁴ Infrequently, the larvae form cysts in the brain, skeletal muscle, bones, kidney, spleen or other tissues.⁵

Bone involvement is seen only in 0.5- 4% of patients.^{5,6} About 50% of the cases of bone hydatid disease affect the spine.⁶⁻⁸ The second most frequent location is the pelvis (21%) followed by the femur

(16%), and tibia (10%).⁶⁻¹⁰ There are case reports of the humerus, skull, ribs and scapula involvement.¹¹⁻¹³

Case Report

A rural 49-year-old woman, a case of hypothyroidism on levothyroxine was referred with purulent discharge from the sinus tract in the left side of the pelvis. She had a six-month history of active draining sinus that began after a car accident (one week before drainage). There were no signs of fracture or abnormality on the plain X-rays after the accident. During this period, she received several courses of antibiotic therapy with impression of osteomyelitis, but there was no improvement. Eventually, she was referred to Chamran Hospital, the main orthopedic center of Fars Province, with impression of chronic osteomyelitis. She did not complain of fever, pain, swelling, limping, and neurologic deficit. In physical examination, purulent, creamy-yellowish discharge from the sinus tract was seen in the mid part of the left ilium. No tenderness, swelling, redness or laceration was detected. The motion of both hips was pain-free and normal. According to our primary diagnosis, i.e., osteomyelitis, we requested Erythrocyte Sedimentation Rate (ESR), C-reactive protein, and culture. ESR and C-reactive protein were 70 mm/h and 12 mg/L, respectively. Wound culture showed light growth of

*Correspondence: Mohammad Jafar Emami, MD, Professor of Orthopaedic Surgery, Research Center for Bone and Joint Diseases, Chamran Hospital, Shiraz University of Medical Sciences, Shiraz, Iran. Tel: +98-711-6234504, Fax: +98-711-6234504, e-mail: emamimj92@yahoo.com

Received: April 21, 2009

Accepted: July 5, 2009

E. coli which was sensitive to cefixime, cephalixin, ceftizoxime and amikacin.

The pelvis X-ray in the anteroposterior direction showed irregular mixed lytic and sclerotic lesions involving most of the left ilium. It extended medially to the sacroiliac joint. There were no linear radiolucent areas suggesting pathological fracture or any periosteal reaction (Figure 1A). Computed tomography also showed multiple lytic lesions in the left ilium with bone fragments in the adjacent soft tissues (Figure 1B).

The patient was admitted in hospital. Antibiotics were begun and she was scheduled for sequestrectomy. During the operation, we unexpectedly encountered small vesicles of different sizes and a destructive bone. There was no specific boundary between healthy and pathologic parts of the bone at that moment, so hydatid disease was diagnosed. Partial excision of the left iliac wing from the iliac crest to the superior part of the acetabulum and to the sacroiliac joint was performed. Histologic examination revealed severe inflammation, granulation tissue formation and foreign body-type reaction surrounding a laminar eosinophilic material (Figure 2). Other parts showed cystic structures with laminating fibrous wall and inner germinal layer diagnostic for hydatidosis. (Figure 3A, B). Then, albendazole (800 mg/day) was started. Abdominal sonography and abdominal and chest CT scan were requested for presence of any other cyst. No other lesion was detected. On the 7th post-op day, the patient was discharged without any discharge from the site of operation while receiving albendazole and antibiotics.

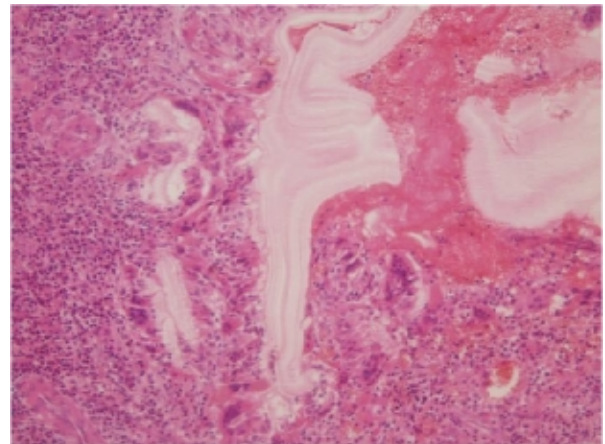


Fig. 2: severe inflammation, granulation tissue formation and foreign body- type reaction surrounding a laminar eosinophilic material (hematoxylin and eosin)

Discussion

Bone hydatid disease is a rare and very slowly progressive disease. It usually occurs in vascularised areas. The vertebrae, ilium, long bones, skull and ribs are most frequently affected. The vertebral column is involved in approximately half of the patient's body because of porto-vertebral shunting.⁹

Hydatid cyst, macroscopically, appears as small vesicles of different sizes. There is no delimitation between healthy and pathologic tissues. Microscopically, the wall of hydatid cyst has three layers:⁵ inner

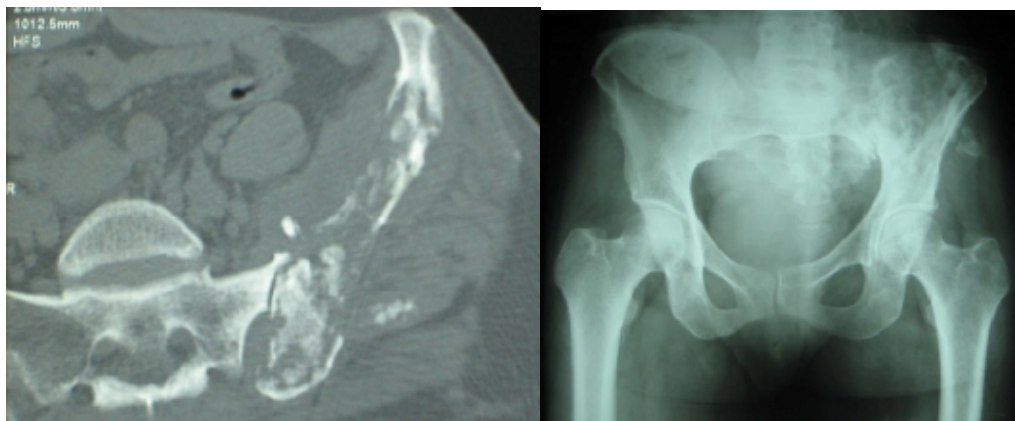

Fig 1B

Fig 1A

Fig. 1: Pelvis X-ray and CT scan show a mixed lytic and sclerotic lesion involving the left iliac wing with ill-defined border. Bone fragments are seen in the adjacent soft

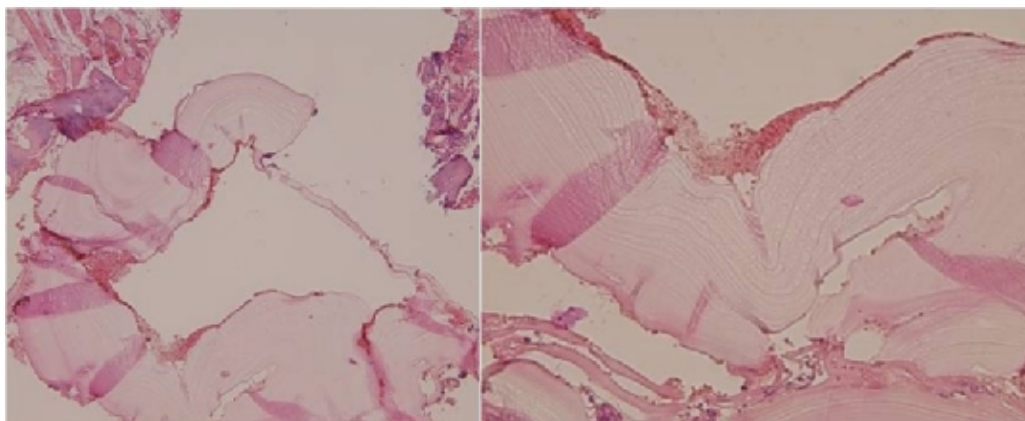


Fig 3A

Fig 3B

Fig. 3: cystic structures with laminating fibrous wall and inner germinal layer diagnostic for hydatidosis (hematoxylin and eosin)

germinal layer, intermediate acellular laminated membrane and outer granulomatous adventitial layer. In the bone, no adventitia is formed. Bone lesions are non-specific and sometimes infected.

Skeletal infestation of *E. granulosus* cyst occurs by hematogenous seeding. The parasite spreads along cancellous trabeculae and medullary canal.¹⁴ As no adventitia is formed around the cyst by the host, daughter cysts can spread to adjacent bones. This can explain why bone hydatid disease is polycystic in contrast to other non-osseous locations.³ On the other hand, rigid structure of the bone does not allow the cyst to grow rapidly. They seldom exceed 2 cm in diameter.¹⁵ The growing cysts lead to bone destruction via three mechanisms including 1) ischemic process through obstruction and compression of the nutrient vessels, 2) mechanical process through compression of the surrounding tissues, 3) a cellular process via osteoclast proliferation. There is no inflammatory reaction of bone except secondary infections which lead to sclerosis, abscess formation, and draining sinuses (like this case).¹⁵

Bone hydatid cyst is a disease of adults. It begins at childhood and may lie dormant and silent in the bone for decades. It occurs more often in men with a mean age of 52.¹⁶ Patients usually present with pain, swelling or pathological fracture. In the spine, neural compression is the chief presentation.

The X-ray appearance is single or multiple expansile osteolytic lesions with cortical thinning.¹⁵ Pathological fracture may cause periosteal reaction. Sclerosis is usually seen in secondary infective hydatid cyst and may be observed in later stages of the disease. Calcification in

the adjacent soft tissue may be detected when the disease invades beyond the bone cortex.

Although CT scan is valuable in depicting hydatid cysts,¹⁰ Magnetic Resonance Imaging (MRI) is the most helpful technique,¹⁷ especially in the soft tissue involvement and spine. CT scan shows well-defined single or multiple cystic lesions that may cause cortical thinning without contrast enhancement. It may also show pathological fracture, cortical destruction and soft tissue extension with calcification.

The diagnosis of hydatid disease is usually late and made intraoperatively, because of slow progression of the disease, absence of specific symptoms, and apparently good health of the patient. Khazim *et al.*¹⁸ reported a mean delay of 6 months between the onset of symptoms and diagnosis in spinal hydatidosis. There is no highly sensitive and specific test for cystic hydatid disease.¹⁹ Diagnostic aspiration of the suspected cyst should never be undertaken due to the risk of anaphylaxis, sensitization and dissemination.^{6,14} Radiographic findings can be helpful especially in sheep-raising areas and in shepherds, veterinarians and butchers or when there is a history of visceral disease.^{6,14}

The most important differential diagnosis of hydatid disease of the ilium is infections, mainly chronic osteomyelitis, and tuberculosis. Giant cell tumor, osteosarcoma, brown tumor, plasmacytoma, multiple myeloma, lymphoma, metastasis, aneurysmal cysts and fibrous dysplasia should be kept in mind when encountering this lesion.^{6,14}

The treatment and prognosis of bone hydatid disease resemble those of a malignant tumor. Surgery is

the treatment of choice. Radical resection of the involved segment is recommended except in areas such as the pelvis, which is technically impossible. Curettage and bone graft is another procedure but with local recurrence rate of 70-80%.²⁰ Yildiz *et al.*²¹ recommended the use of polymethyl methacrylate, as they are afraid that the graft may be invaded by recurrent hydatid infection. Scolicidal solutions including hypertonic saline, formalin, silver nitrate, sodium hypochlorite and glycerin should be used to prevent recurrence.¹⁸

Adjuvant medical therapy can control the disease locally, prevent recurrence and avoid systematic spread. Benzimidazole derivative and mebendazole could kill the germinal membrane in mice by limiting the glucose uptake.²² Albendazole, a relatively new compound, is now regarded by the World Health Organization as the agent of first choice to treat hydatid

disease, because of better absorption and higher levels in the cysts and blood.²³ Albendazole is given at 15 mg/kg daily in courses of 28 days followed by an interval of 14 days between them. One course is given preoperatively and six or more courses postoperatively.²⁴ Teggi²⁵ advocated continuous treatment without a break, especially for bone hydatid disease. A treatment period of 2 years may be necessary although sometimes lifelong treatment is recommended. If albendazole alone is not effective, praziquantel can be added.²⁴ This regimen can be used for patients with multiple recurrences and those unsuitable for surgery. The diagnosis of primary bone hydatid disease is difficult and requires a high index of suspicion; therefore, orthopaedic surgeons should be aware of this disease, especially in endemic areas.

Conflict of interest: None declared.

References

- Mehrabani D, Oryan A, Sadjadi SM. Prevalence of *Echinococcus granulosus* infection in stray dogs and herbivores in Shiraz, Iran. *Vet Parasitol* 1999;**86**:217-20.
- Song XH, Ding LW, Wen H. Bone hydatid disease. *Postgrad Med J* 2007;**83**:536-42. [17675547] [doi:10.1136/pgmj.2007.057166]
- Papanikolaou A. osseous hydatid disease. *Trans R Soc Trop Med Hyg* 2008;**102**:233-8. [17996916] [doi:10.1016/j.trstmh.2007.09.012]
- Eckert J, Deplazes P. Biological, epidemiological, and clinical aspects of echinococcosis, a zoonosis of increasing concern. *Clin Microbiol Rev* 2004;**17**:107-35. [14726458] [doi:10.1128/CMR.17.1.107-135.2004]
- Polat P, Kantarci M, Alper F, Suma S, Koruyucu MB, Okur A. Hydatid disease from head to toe. *Radiographics* 2003;**23**:475-94. [12640161] [doi:10.1148/rg.232025704]
- Zliti M, Ezzaoula K, Lebib H, Karray M, Kooli M, Mestiri M. Hydatid cyst of bone: diagnosis and treatment. *World J Surg* 2001;**25**:75-82. [11213159] [doi:10.1007/s002680020010]
- Govender TS, Aslam M, Parbhoo A, Corr P. Hydatid disease of the spine. A long-term followup after surgical treatment. *Clin Orthop Relat Res* 2000;**(378)**:143-7. [10986988] [doi:10.1097/00003086-200009000-00023]
- Mohammadi AA, Sabet B, Amini M, Mohammadi MK. Short-course combination therapy with albendazole and praziquantel chemotherapy in recurrent complicated case of vertebral hydatidosis. *Iranian Red Crescent Med J* 2009;**10**:238-40.
- Morris BS, Madiwale CV, Garg A, Chavhan GB. Hydatid disease of bone: a mimic of other skeletal pathologies. *Australas Radiol* 2002;**46**:431-4. [12452919] [doi:10.1046/j.1440-1673.2002.t01-1-01099.x]
- Tüzün M, Hekimoğlu B. Pictorial essay. Various locations of cystic and alveolar hydatid disease: CT appearances. *J Comput Assist Tomogr* 2001;**25**:81-7. [11176298] [doi:10.1097/00004728-200101000-00014]
- Ferrandez HD, Gomez-Castresana F, Lopez-Duran L, Mata P, Brandau D, Sanchez-Barba A. Osseous hydatidosis. *J Bone Joint Surg Am* 1978;**60**:685-90. [681391]
- Ozkan H, Dogramaci Y, Kose O, Esen E, Erdem H, Komurcu M. Primary hydatid disease of the humerus. *Ann Acad Med Singapore* 2008;**37**:440-1. [18536837]
- Arya B, Golalipour MJ, Azarnoosh R. Soft tissue hydatid cyst in the right temporal region. *Iranian Red Crescent Med J* 2005;**8**:95-97.
- Herrera A, Martinez AA. Extraspinal bone hydatidosis. *J Bone Joint Surg Am* 2003;**85-A**:1790-4. [12954839]
- Diedrich O, Kraft CN, Zhou H, Sommer T, Perlick L, Schmitt O. Orthopedic aspects of osseous echinococcosis-radiologic diagnosis, current surgery and drug therapy aspects. *Z Orthop Ihre Grenzgeb* 2001;**139**:261-6. [11486632]
- Markakis P, Markaki S, Prevedorou D, Bouropoulou V. Echinococcosis of bone: clinico-laboratory findings and differential diagnostic problems. *Arch Anat Cytol Pathol* 1990;**38**:92-4. [2363594]
- Singh S, Korah IP, Gibikote SV, Shyam NK, Nair A, Korula A. Sacral hydatidosis value of MRI in the diagnosis. *Skeletal Radiol* 1998;**27**:518-21. [9809883] [doi:10.1007/s002560050431]
- Khazim R, Fares Y, Heras-Palou C, Ruiz Barnes P. Posterior decompression of spinal hydatidosis: long term results: Fundacion Jimenez Diaz, Madrid, Spain. *Clin Neurol Neurosurg* 2003;**105**:209-14. [128 60516] [doi:10.1016/S0303-8467(03)00013-1]
- Siracusano A, Buttari B, Delunardo F, Profumo E, Margutti P, Ortona E, Rigano R, Teggi A. Critical Points in the immunodiagnosis of cystic echinococcosis in humans. *Parassitologia* 2004;**46**:401-3. [16044700]
- Papanikolaou A, Antoniou N, Pavlakis D, Garas G. Hydatid disease of the tarsal bones. a case report. *J Foot Ankle Surg* 2005;**44**:396-400. [16210160] [doi:10.1053/j.jfas.2005.07.004]
- Yildiz Y, Bayrakci K, Altay M, Saglik Y. The use of polymethylmethacrylate in the management of hydatid disease of bone. *J Bone Joint Surg Br* 2001;**83**:1005-8. [11603512] [doi:10.1302/0301-620X.83B7.12105]

- 22 Heath DD, Chevis RA. Mebendazole and hydatid cyst. *Lancet* 1974;**2**:218-9. [4136160] [doi:10.1016/S0140-6736(74) 91517-7]
- 23 Chen Geng, shi Dazhong. The treatment status for hydatid disease. *Endemic disease Bulletin*, 2001.
- 24 Bonifacino R, Dogliani E, Craig PS. Albendazole treatment and serological follow up in hydatid disease of the bone. *Int Orthop* 1997;**21**:127-32. [9195269] [doi:10.1007/s002640050135]
- 25 Teggi A. An up-to-date on clinical management of human cystic echinococcosis. *Parassitologia* 2004; **46**:405-7. [16044701]